

# ACG Clinical Guidelines: Diagnosis and Management of Achalasia

Michael F. Vaezi, MD, PhD, MSc, FACP<sup>1</sup>, John E. Pandolfino, MD, MS, FACP<sup>2</sup>, Rena H. Yadlapati, MD, MHS (GRADE Methodologist)<sup>3</sup>, Katarina B. Greer, MD, MS<sup>4</sup> and Robert T. Kavitt, MD, MPH<sup>5</sup>

**Achalasia is an esophageal motility disorder characterized by aberrant peristalsis and insufficient relaxation of the lower esophageal sphincter. Patients most commonly present with dysphagia to solids and liquids, regurgitation, and occasional chest pain with or without weight loss. High-resolution manometry has identified 3 subtypes of achalasia distinguished by pressurization and contraction patterns. Endoscopic findings of retained saliva with puckering of the gastroesophageal junction or esophagram findings of a dilated esophagus with bird beaking are important diagnostic clues. In this American College of Gastroenterology guideline, we used the Grading of Recommendations Assessment, Development and Evaluation process to provide clinical guidance on how best to diagnose and treat patients with achalasia.**

*Am J Gastroenterol* 2020;115:1393–1411. <https://doi.org/10.14309/ajg.0000000000000731>; published online August 10, 2020

## INTRODUCTION

Achalasia is one of the most studied esophageal motility disorders. In this guideline, we address the diagnosis, treatment, and overall management of adult patients with achalasia. This guideline is structured in the format of recommendations, key concepts, and summaries of the evidence. Each recommendation statement has an associated assessment of the quality of evidence and strength of recommendation based on the Grading of Recommendations Assessment, Development, and Evaluation (GRADE) process. Key concepts are statements that are not amenable to the GRADE process, either because of the structure of the statement or the available evidence. In some instances, key concepts are based on the extrapolation of evidence and/or expert opinion. The evidence summary for each section provides important definitions and data supporting the recommendations.

## METHODS

Each section will provide specific recommendations based on the current literature and a summary of the evidence supporting those recommendations. We used the GRADE process (Table 1) for each of the recommendation statements (Table 2). Two formally trained GRADE methodologists conducted the GRADE process using GRADEPro. This process evaluated the quality of supporting evidence. The quality of the evidence is graded from high to low. “High”-quality evidence indicates that further research is unlikely to change the authors’ confidence in the estimate of effect and that we are very confident that the true effect lies close to that of the estimate of the effect. “Moderate”-quality evidence is associated with moderate confidence in the effect estimate, although further research would be likely to have an impact on the confidence of the estimate, whereas “low”-quality evidence indicates that further study would likely have an important

impact on the confidence in the estimate of the effect and would likely change the estimate. “Very low”-quality evidence indicates very little confidence in the effect estimate and that the true effect is likely to be substantially different than the estimate of effect. A “strong” recommendation is made when the benefits clearly outweigh the negative, whereas a “conditional” recommendation is used when some uncertainty remains about the balance of benefit and potential harms. Key concepts are statements that are not amenable to the GRADE process, either because of the structure of the statement or because of the available evidence. In some instances, key concepts are based on the extrapolation of evidence and/or expert opinion. Tables 2 and 3 summarize the GRADE recommendations and key concept statements in this guideline.

## EPIDEMIOLOGY AND DIAGNOSIS

Achalasia is an esophageal motility disorder with reported global incidence and prevalence ranging from 0.03 to 1.63 per 100,000 persons per year and 1.8 to 12.6 per 100,000 persons per year, respectively (1,2). Achalasia is a rare diagnosis with only 20,000–40,000 affected patients in the United States. It occurs equally in men and women, with no racial predilection. The peak incidence occurs between 30 and 60 years of age. Patients often present with progressive dysphagia to solids and liquids, heartburn, chest pain, regurgitation, and varying degrees of weight loss or nutritional deficiencies (1,3). Diagnosis of achalasia is thus clinically suspected in patients who present with the above-mentioned classic symptoms and then confirmed by objective diagnostic tests discussed below. However, because heartburn may be present in 27%–42% of patients with achalasia, patients are frequently initially misdiagnosed as having gastroesophageal reflux disease (GERD) and are treated with proton pump inhibitors (PPI) (4).

<sup>1</sup>Division of Gastroenterology, Hepatology, and Nutrition, Vanderbilt University School of Medicine, Nashville, Tennessee, USA; <sup>2</sup>Division of Gastroenterology and Hepatology, Northwestern University Feinberg School of Medicine, Chicago, Illinois, USA; <sup>3</sup>Division of Gastroenterology, University of California San Diego School of Medicine, San Diego, California, USA; <sup>4</sup>Division of Gastroenterology and Liver Disease, University Hospitals Cleveland Medical Center, Cleveland, Ohio, USA; <sup>5</sup>Section of Gastroenterology, Hepatology, and Nutrition, University of Chicago Medicine, Chicago, Illinois, USA. **Correspondence:** Michael F. Vaezi, MD, PhD, MSc, FACP. E-mail: michael.vaezi@VUMC.org.

Received September 12, 2019; accepted May 5, 2020

**Table 1. GRADE quality criteria**

Study design	Quality of evidence	Reduced factors	Increased factors
Randomized trials	High	Risk of bias	Large effect
		–1 serious	+1 large
	Moderate	–2 very serious	+2 very large
		Inconsistency	Dose response
		–1 serious	+1 if gradient
		–2 very serious	
Observational studies	Low	Indirectness	Confounding
		–1 serious	+1
	Very low	–2 very serious	
		Imprecision	
		–1 serious	
		–2 very serious	
	Publication bias		
	–1 likely		
	–2 very likely		

GRADE, Grading of Recommendations Assessment, Development and Evaluation.

### Recommendation

1. We recommend that patients who are initially suspected of having GERD but do not respond to acid-suppressive therapy should be evaluated for achalasia.

An incorrect GERD diagnosis often leads to a significant delay in achalasia diagnosis until patients have persistent symptoms that eventually lead to the correct diagnostic studies.

### Pathophysiology

Achalasia is an incurable disease, and the underlying etiology remains unknown. The primary etiology of achalasia is believed to be selective loss of inhibitory neurons in the myenteric plexus of the distal esophagus and lower esophageal sphincter (LES), resulting in a neuronal imbalance of excitatory and inhibitory activity. Excitatory neurons release acetylcholine, whereas inhibitory neurons primarily release vasoactive intestinal peptide

**Table 2. Summary and strength of GRADE recommendations for achalasia**

Statement	GRADE quality	Recommendation strength
Diagnosis and assessment		
We recommend that patients who are initially suspected of having GERD but do not respond to acid-suppressive therapy should be evaluated for achalasia.	Very low	Strong
We recommend using esophageal pressure topography over conventional line tracing for the diagnosis of achalasia.	High	Strong
We suggest that classifying achalasia subtypes by the Chicago Classification may help inform both prognosis and treatment choice.	Low	Conditional
Initial treatment (medical therapy, pneumatic dilation, surgical myotomy, and POEM)		
In patients with achalasia who are candidates for definite therapy:		
• PD, LHM, and POEM are comparable effective therapies for type I or type II achalasia.		
• POEM would be a better treatment option in those with type III achalasia.		
• Botulinum toxin injection is reserved for those who cannot undergo the above definitive therapies.		
We suggest that POEM or PD result in comparable symptomatic improvement in patients with types I or II achalasia.	Low	Conditional
We recommend that POEM and LHM result in comparable symptomatic improvement in patients with achalasia.	Moderate	Strong
We recommend tailored POEM or LHM for type III achalasia as a more efficacious alternative disruptive therapy at the LES compared to PD.	Moderate	Strong

**Table 2. (continued)**

Statement	GRADE quality	Recommendation strength
We recommend that PD is superior to medical therapy in relieving symptoms and physiologic parameters of esophageal emptying.	Very low	Strong
We recommend that PD or LHM are both effective and equivalent short- and long-term procedures for patients with achalasia who are candidates to undergo definitive therapy.	High	Strong
We recommend LHM over botulinum toxin injection in patients with achalasia fit for surgery.	Moderate	Strong
We recommend botulinum toxin injection as first-line therapy for patients with achalasia who are unfit for definitive therapies compared with other less effective pharmacological therapies.	Moderate	Strong
We suggest that previous treatment with botulinum toxin injection does not significantly affect performance and outcomes of myotomy.	Low	Conditional
We recommend that myotomy with fundoplication is superior to myotomy without fundoplication in controlling distal esophageal acid exposure.	Moderate	Strong
We suggest either Dor or Toupet fundoplication to control esophageal acid exposure in patients with achalasia undergoing surgical myotomy.	Moderate	Conditional
We recommend against stent placement for management of long-term dysphagia in patients with achalasia.	Low	Strong
Post-therapy assessment		
We recommend against obtaining routine gastrograffin esophagram after dilation. This test should be reserved for patients with a clinical suspicion for perforation after dilation.	Low	Strong
We suggest that ES or HRM alone not be used to define treatment failure in evaluating continued or recurrent symptoms after definitive therapy for achalasia.	Very low	Strong
We recommend using TBE as the first-line test in evaluating continued or recurrent symptoms after definitive therapy for achalasia.	Very low	Strong
We suggest that in patients with achalasia, POEM compared with LHM with fundoplication or PD is associated with a higher incidence of GERD.	Moderate	Strong
Post-failed initial therapies		
We recommend that PD is an appropriate and safe treatment option for patients with achalasia post-initial surgical myotomy or POEM in need of retreatment.	Moderate	Strong
We suggest that POEM is a safe option in patients with achalasia who have previously undergone PD or LHM.	Low	Strong
We suggest that Heller myotomy be considered before esophagectomy in patients who have failed PD and POEM if the anatomy is conducive, and there is evidence of incomplete myotomy.	Very low	Strong
We recommend esophagectomy in surgically-fit patients with megaesophagus who have failed other interventions.	Low	Strong
Cancer surveillance		
We suggest against routine endoscopic surveillance for esophageal carcinoma in patients with achalasia.	Low	Strong

ES, Eckardt score; GERD, gastroesophageal reflux disease; GRADE, Grading of Recommendations Assessment, Development and Evaluation; HRM, high resolution manometry; LES, lower esophageal sphincter; LHM, laparoscopic Heller myotomy; PD, pneumatic dilation; POEM, peroral endoscopic myotomy; TBE, timed barium esophagram.

and nitric oxide (5). A localized decrease of vasoactive intestinal peptide and nitric oxide with unopposed excitatory activity causes failure of LES relaxation and disruption of esophageal peristalsis (6,7).

**Diagnostic testing**

*Endoscopy, barium esophagram, and esophageal manometry* are 3 well established and often complementary tests in establishing the diagnosis of achalasia. Endoscopic findings of retained saliva

(Figure 1a) with a puckered gastroesophageal junction (Figure 1b) or barium swallow showing a dilated esophagus with bird beaking (Figure 1c) are important diagnostic clues. In early achalasia, barium esophagram showing retention of barium above the gastroesophageal junction may at times be misinterpreted as a reflux-related stricture or missed completely. Endoscopy is more likely to show a classic appearance in a moderate to severely dilated esophagus and less likely in those with early disease. Endoscopy also plays a pivotal role in

Downloaded from https://journals.lww.com/ajg by BMDM5ePHKav1ZEoum1IQIN4a4kLJHEZgbsIH04XMI0hCwCXC1AWM on 09/15/2023

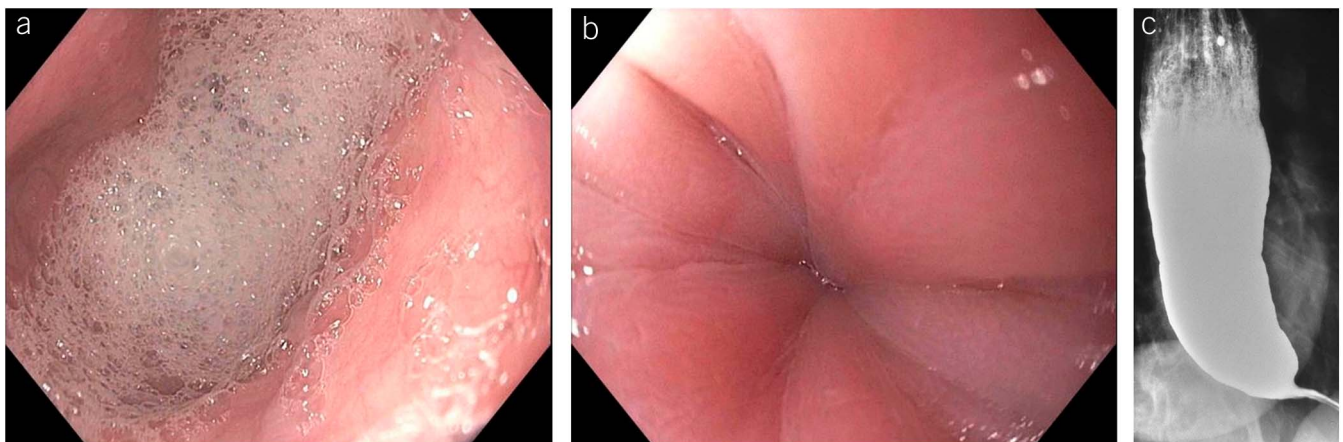
**Table 3. Key concept statements**

Statement
Timed barium esophagram showing retained barium and bird beaking in the appropriate clinical presentation may be diagnostic of achalasia.
Endoscopic signs of dilated esophagus with retained saliva and food with puckered and tight gastroesophageal junction to the passage of endoscope should raise clinical suspicion for achalasia.
FLIP can be complementary in the evaluation of patients with achalasia before and after treatment.
Pharmacologic therapy in achalasia should be reserved for those who cannot undergo definitive therapy and have failed botulinum toxin injection.
Serial pneumatic dilation is the most effective non-surgical treatment option for patients with achalasia.
Recommendations
In young male patients with achalasia, PD with larger balloon sizes (3.5 cm then 4 cm) or myotomy or POEM may be more effective than initial PD with the 3 cm balloon size.
Patients with suspected achalasia based on clinical presentation should always undergo upper endoscopy to rule-out pseudoachalasia from an obstructing mass.
FLIP, functional lumen imaging probe; PD, pneumatic dilation.

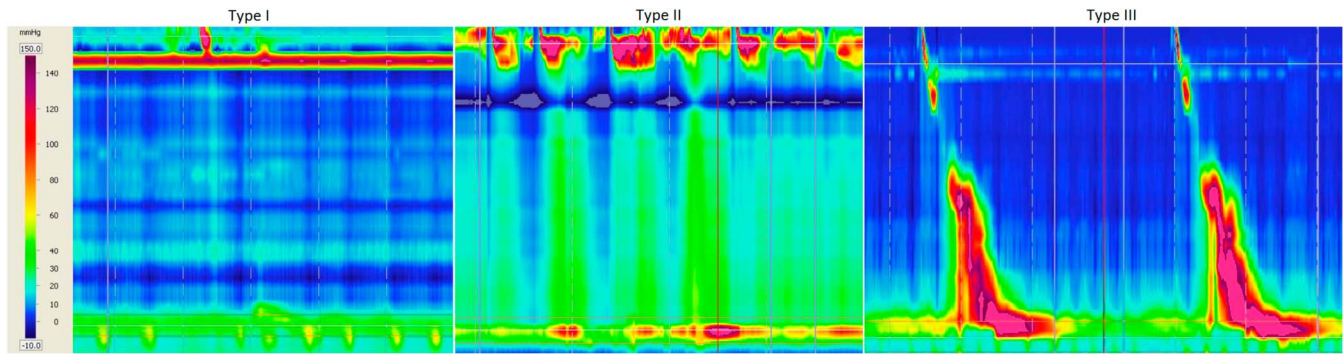
excluding pseudoachalasia or other mechanical obstruction that may result in symptoms similar to achalasia. A significant short-term weight loss in elderly patients with suspected achalasia should alert providers to the possibility of pseudoachalasia. In such cases, cross-sectional imaging and/or endoscopic ultrasound may be used for establishing the correct diagnosis. Endoscopy is useful in patients after therapy who have recurrence of symptoms to assess for reflux and possible reflux-related stricture vs recurrence of achalasia. Barium esophagram can be complementary in patients whose manometric findings are equivocal or not classic. Timed barium esophagram (discussed in the “Post-Therapy Assessment” section) was developed to guide providers not only in suspecting the diagnosis of achalasia but also to help guide post-therapy success. Barium column height at 1-, 2-, and 5-minutes after ingestion of a large barium bolus determines the retention of barium and rate of emptying. Thus, in the appropriate clinical setting, achalasia can be diagnosed with esophagram findings of retained barium and bird beaking and/or endoscopic signs of a dilated esophagus with retained saliva and food with a puckered and tight esophagogastric junction (EGJ).

The diagnosis of achalasia is confirmed with high-resolution manometry (HRM), which is the current gold standard test (8). HRM leverages improved space-time resolution and a more

intuitive description of contractile and pressure patterns to refine the classification of motor dysfunction that was originally described using conventional low-resolution pressure tracing manometry. The main benefits of this classification are an improved accuracy, an ability to distinguish clinically relevant subtypes, and a higher level of reproducibility. The achalasia subtypes represent the foundation of the Chicago Classification, and this approach advanced our understanding of achalasia as a heterogeneous disease with distinct patterns of pressurization and contraction in the body of the esophagus (9). Achalasia is now recognized to present with 3 distinct manometric subtypes (Figure 2). All 3 subtypes have impaired EGJ relaxation, but the distinguishing features are the pattern of esophageal pressurization and contraction. Achalasia type I (second most common; 20%–40% of cases) is characterized by 100% failed peristalsis (aperistalsis) with the absence of panesophageal pressurization to more than 30 mm Hg, achalasia type II (most common; 50%–70% of cases) is characterized by 100% failed peristalsis (aperistalsis) with panesophageal pressurization to greater than 30 mm Hg, and achalasia type III (least common; 5% of cases) is characterized by spastic contractions because of abnormal lumen obliterating contractions with or without periods of panesophageal pressurization (9).



**Figure 1.** (a) Endoscopic appearance of foam and saliva in the esophagus in achalasia. (b) Puckering of gastroesophageal junction requiring more than usual pressure to traverse in achalasia. (c) Barium swallow showing dilated esophagus with retained barium and “bird beaking.”



**Figure 2.** High resolution manometry of achalasia phenotypes: type I-absent pressurization (left), type II-pan pressurization (middle), and type III-spastic contractions (right). Lower esophageal sphincter relaxation is impaired for all subtypes.

Correct diagnosis, treatment, and management of patients with achalasia is crucial to ensure optimal patient outcome.

In a blinded multicenter study by Carlson et al. (10) esophageal pressure topography was shown to have superior inter-rater agreement and diagnostic accuracy compared with conventional manometry. The total agreement in the study was moderate for esophageal pressure topography ( $\kappa = 0.57$ ; 95% confidence interval [CI]: 0.56–0.59) and fair for conventional manometry ( $\kappa = 0.32$ ; 0.30–0.33), and the odds for an incorrect diagnosis was 3.4 times higher with conventional manometry. In addition, Roman et al. (11) performed a randomized trial in which 124 patients underwent conventional manometry and 123 patients underwent esophageal pressure topography to determine diagnostic accuracy in unexplained dysphagia. This study reported a higher yield of making the diagnosis of achalasia (26% vs 12%) and a higher degree of diagnostic confirmation on follow-up (89% vs 81%) with esophageal pressure topography compared with conventional manometry, respectively. Similarly, additional studies have supported high rates of inter- and intra-rater agreement for achalasia (12–14).

### Recommendation

2. Based on the inherent benefit of improved detail in describing esophageal pressurization and contractile patterns using esophageal pressure topography and superior accuracy and reproducibility in diagnosing achalasia in both randomized controlled and blinded comparison studies, we recommend using esophageal pressure topography over conventional line tracing for the diagnosis of achalasia.

In the era before HRM and esophageal pressure topography, patients with achalasia were grouped as a single disease and were offered various treatment modalities focused on disrupting the LES via dilation or myotomy. The treatment decision was not tailored based on physiology or anatomy and was primarily driven by the expertise of the treating physician and the patient's preference. Although most studies suggest very good outcomes over a short duration, treatment failures over the first 1–5 years could be as high as 10%–20%. The achalasia subtypes in the Chicago Classification were created to subtype vigorous achalasia and variants into a more uniform scheme to determine whether these subtypes had different pathogenic features and response to therapy (9). The achalasia subtypes were found to differ in prevalence, degree of esophageal dilatation, and underlying opioid utilization, and there was also observational evidence of patients progressing across the subtypes typically starting with

type III and moving to type II (9). This signature was consistent with the typical description of the progression of disease because it relates to dilatation as type I patients were typically more dilated than type II patients. These initial findings led to multiple studies that assessed treatment outcomes, and a consistent pattern emerged where type II patients seemed to have the best outcome, whereas type III patients tended to do poorly with treatments that were confined to the LES or short myotomies (15–20). Two recent meta-analyses also support that achalasia subtypes defined in the Chicago Classification have prognostic value and varying outcomes across therapies (21,22).

More recently, there have been additional studies focused on single therapies (Heller myotomy, POEM) and the achalasia subtypes. Three studies assessing the effect of Heller myotomy across the achalasia subtypes suggested only mild differences or similar outcomes (23,24). These findings are in line with the previous findings supporting better outcomes with surgery for type I and type III based on a more robust disruption and a longer myotomy. Even better results have been found with POEM across the subtypes (25,26), and one study actually found that type III patients performed better with POEM (98% response) vs Heller myotomy (80%) (27). This also suggests that the longer myotomy may be an important component of treatment for type III achalasia. Tailored POEM, which typically extends the myotomy further than Heller myotomy, seems to be even more effective in this subtype, (27) and thus, identifying type III achalasia has implications in treatment decisions.

### Recommendation

3. Based on these observations, we suggest that classifying achalasia subtypes by the Chicago Classification may help inform both prognosis and treatment choice because type II patients have very good outcomes, regardless of which therapy is selected, and type III patients require a more extensive myotomy.

The functional lumen imaging probe (FLIP) is a high-resolution impedance system that is approved by the U.S. Food and Drug Administration to study the pressure geometry relationship and motor function of the esophagus (28). Its role in the diagnosis of achalasia and post-therapy assessment of patients is evolving. By assessing simultaneous cross-sectional area and pressure (distensibility), the FLIP device can depict the pressure geometry relationship in a simulated 3D model, and this approach is useful in assessing the EGJ opening dynamics in

achalasia (29). FLIP has also been shown to be a useful tool in diagnosing achalasia and has a high concordance with manometry and may help in equivocal cases where manometry fails to diagnose achalasia despite a high clinical suspicion. In a small study that included 13 patients with typical symptoms of achalasia, Eckardt score (ES) of 7 (5–7), and normal EGJ pressures despite abnormal esophageal stasis, the EGJ distensibility index was diagnostic of poor EGJ opening (0.8 [0.7–1.2] mm<sup>2</sup>/mm Hg) and modified the treatment strategy (30). FLIP panometry is shown to be sensitive and accurate in diagnosing achalasia compared with HRM. In a study of 145 patients undergoing blinded analysis of FLIP assessment and HRM, a manometric diagnosis of achalasia was made in 70 patients, and all 70 patients were identified to have reduced EGJ distensibility by FLIP (31). FLIP may also be useful in evaluating patients who cannot tolerate or complete a standard manometry because FLIP is performed during endoscopy while the patient is sedated. Further studies are required to determine whether FLIP can replace or reduce the number of manometry studies and barium esophagrams in the management of achalasia because the potential of performing this study during the index endoscopy has cost-effectiveness implications.

Based on consistent but low-quality data, the role of FLIP in achalasia is evolving, and it may be helpful in patients who cannot tolerate manometry and also may function as an arbiter in difficult cases before and after treatment.

### INITIAL TREATMENT OPTIONS

It is important to recognize that achalasia is a chronic condition without a cure. All current treatment options in achalasia are palliative in nature and aim to reduce the hypertonicity of the LES. The ultimate goals of therapy include reducing symptoms, improving esophageal emptying, and preventing further dilation of the esophagus. The currently available treatment options in achalasia include pharmacologic, endoscopic, and surgical means. A tailored approach with the available treatment options can help patients achieve the outlined goals of therapy.

#### Oral pharmacologic therapy

Pharmacologic therapy is the least effective treatment option in achalasia. Calcium channel blockers (nifedipine 10–30 mg sublingual before meals) and nitrates (sublingual isosorbide dinitrate 5 mg before meals) are the 2 most commonly used medications in treating achalasia (32–40). The mechanisms through which they function include the release of nitrous oxide in the latter and reduction of intracellular calcium in the former, leading to relaxation of the LES. Other less commonly used medical therapies include anticholinergics (atropine, dicyclomine, and cimetropium bromide), (beta)-adrenergic agonists (terbutaline), and theophylline (41–43). Sildenafil (50 mg) has also shown some efficacy in treating patients with achalasia (44,45). Overall, pharmacotherapy in achalasia results in a short-term decrease of LES pressure in 13%–65% of patients resulting in symptom improvement in 0%–87% of patients (32). Short duration of action (30–120 minutes) necessitates multiple daily dosing which may lead to side effects of headache, hypotension, and pedal edema. Despite the lack of comparative trials, more definitive therapies seem to have higher and more durable efficacy in achalasia, and pharmacotherapy should be used only for patients with achalasia who are not candidates for definitive therapies of pneumatic

dilation (PD), laparoscopic Heller myotomy (LHM), or POEM and have failed botulinum toxin injection.

#### Endoscopic pharmacologic therapy

Botulinum toxin is a potent presynaptic inhibitor of acetylcholine release from nerve endings that has proven to be a useful treatment in achalasia (46). The toxin cleaves the protein (SNAP-25) involved in fusing presynaptic vesicles containing acetylcholine with the neuronal plasma membrane in contact with the target muscle. This, in turn, inhibits exocytosis of acetylcholine into the synaptic area and causes a short-term paralysis of the muscle by blocking the unopposed cholinergic stimulation of the LES, which is devoid of inhibitory influence in achalasia. This effect interrupts the neurogenic component of the sphincter; however, it has no effect on the myogenic influence maintaining basal LES tone. Thus, the treatment is limited, and most treatment effects are associated with an approximate 50% reduction in the basal LES pressure (47). This reduction may be sufficient to allow esophageal emptying when esophageal pressure rises to a level where it can overwhelm the partially paralyzed LES.

Botulinum toxin injection is straightforward to administer and is associated with low rates of complications, although rare cases of reflux and mediastinitis may occur. 100 U of botulinum toxin is delivered above the squamocolumnar junction using a sclerotherapy needle in 0.5–1 mL aliquots. Escalating doses above 100 U have not been shown to have superior treatment benefit. A systematic review (48) has shown that based on 9 studies in 315 patients, symptom relief is reported after botulinum toxin in 78.7% of patients evaluated within 30 days of treatment. Symptom relief declines in months after treatment, with 70% symptom relief at 3 months, 53.3% relief at 6 months, and 40.6% relief at 12 months. In this systematic review, additional injections for symptom relief were needed in 46.6% of patients, and 30% of patients required additional treatments for symptom relief comprising either repeated botulinum toxin injection, dilatation, or surgery. Botulinum toxin can provide effective initial treatment results with only slightly lower effectiveness compared with myotomy; however, this treatment benefit quickly dissipates over time, making it a suboptimal intervention for patients with reasonable life expectancy fit for endoscopic or surgical interventions. Botulinum toxin is the best studied pharmacotherapy in achalasia, and it is the most effective pharmacological treatment that can be offered; however, its benefits are short lived, and the medication should not be offered as first-line treatment to patients who are fit for myotomy.

#### Recommendation

4. We recommend botulinum toxin injection as first-line therapy for patients with achalasia that are unfit for definitive therapies compared with other less-effective pharmacological therapies.

#### Impact of botulinum toxin before other definitive therapies.

Effects of botulinum toxin on tissue scarring was examined in an animal study where esophagi from swine treated by botulinum toxin or pneumatic dilatation were compared with those who did not receive any endoscopic intervention (49). Hematoxylin and eosin stains from treated animals showed severe inflammatory changes consistent with reflux and mild fibrosis. Clinical data published by Patti et al. (50) suggested deleterious effect of

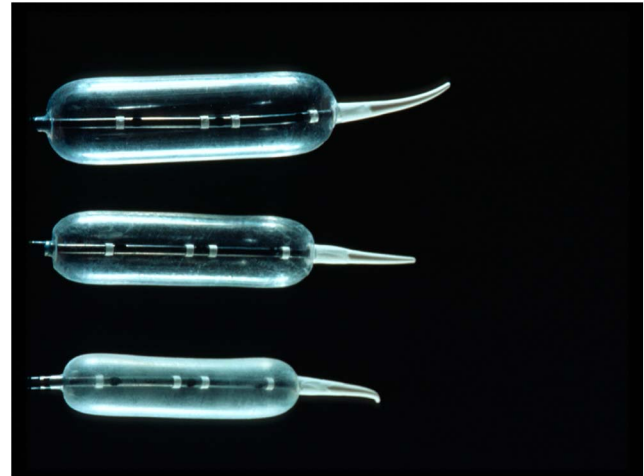
previous botulinum toxin on myotomy outcomes. In an observational study design, these authors followed 44 patients with achalasia; 16 were treated by laparoscopic myotomy and Dor fundoplication, 10 were treated by botulinum toxin, and the remainder were treated by pneumatic dilatation. Reported outcomes included anatomical planes identified at surgery, esophageal perforation, and percentage of patients with good/excellent results after intervention. Histological samples were not obtained to confirm the presence and degree of tissue fibrosis. In patients who did not have symptomatic relief with botulinum toxin, surgery was technically straightforward, and the outcome was excellent. In patients who responded to botulinum toxin injection, the LES became fibrotic, and relief of dysphagia was not as robust. Smith et al. (51) retrospectively analyzed 209 patients undergoing Heller myotomy for achalasia. Fifty-four patients were treated using botulinum toxin alone, or in combination with pneumatic dilatation. Complications including dysphagia and perforation were seen in 10.4% who had previous endoscopic treatment compared with 5.4% of patients who were only treated by surgical myotomy ( $P < 0.05$ ). Previous botulinum toxin did not seem to increase the likelihood of complications of POEM. Patients who had previous treatment with botulinum toxin or surgical myotomy had similar intraoperative times, length of stay after surgery, and dysphagia scores after POEM. The follow-up period in these studies was less than 2 years (52,53). Evidence regarding potential harms of botulinum toxin before surgical and endoscopic myotomies is conflicting, and it is possible that uncertainty regarding negative effects of previous botulinum toxin stems from the fact that data are derived from observational studies that included small number of patients and limited follow-up periods.

### Recommendation

5. We recommend that treatment with botulinum toxin injection does not significantly affect performance and outcomes of myotomy.

### Pneumatic dilation

PD is an effective option for patients with achalasia (1). Standard dilators are not effective in disrupting the muscularis propria needed for symptom relief in this group of patients. All patients considered for PD must also be candidates for surgery in the event of esophageal perforation needing repair which is reported in 1.9% (range 0%–10%). The most commonly used balloon dilator for achalasia is the nonradiopaque graded size polyethylene balloon (Rigiflex dilators). The procedure is always performed under sedation with or without fluoroscopy. The dilators come in 3 sizes (3.0, 3.5, and 4.0 cm) and are often used in a graded fashion (3.0 cm first, followed by 3.5 cm and then 4.0 cm) (Figure 3). The most important aspect of PD is the expertise of the operator and the institutional backup for surgical intervention in case of perforation. Accurate fluoroscopic (Figure 4a) or endoscopic positioning (Figure 4b) of the balloon across the LES is important in its effectiveness. The pressure required to obliterate the fluoroscopic waist or to maximum balloon dilation endoscopically is usually 10–15 psi of air held for 15–60 seconds. Patients are often observed in recovery for any signs of perforation (pain, crepitus, and fever). Radiographic testing by gastrograffin/barium esophagram and/or computed tomography scan of abdomen/chest studies would be indicated if perforation is suspected. Otherwise, patients can be discharged home with antiemetics and instructions to call

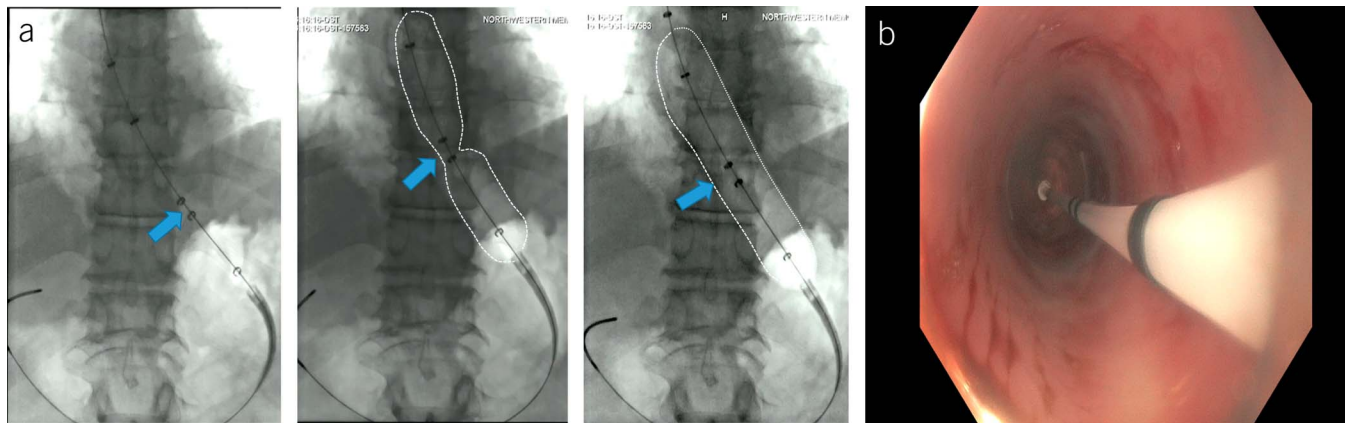


**Figure 3.** Pneumatic dilator sizes 3.0 cm (bottom), 3.5 cm (middle), and 4.0 cm (top) used in treating patients with achalasia. Graded approach of starting with the smaller 3.0-cm balloon and progressing to the larger sizes if failed therapy is recommended in all except younger male patients in whom initial approach with 3.5-cm balloon may be used.

if they develop severe chest pain with or without fever as delayed perforation after the procedure is possible.

Good to excellent relief of symptoms is possible in 50%–93% of patients after PD (1). Cumulatively, dilation with 3.0-, 3.5-, and 4.0-cm balloon diameters result in good to excellent symptom relief in 74%, 86%, and 90% of patients with an average follow-up of 1.6 years (range 0.1–6 years). Initial dilation using a 3-cm balloon is recommended for most patients, followed by symptomatic and objective assessment in 4–6 weeks. In those who continued to be symptomatic, the next size dilator may be used. This approach is reasonable in all except a few patients with less favorable clinical response to the initial dilation with the 3.0-cm balloon. Therefore, serial PD is an effective treatment option for patients with achalasia for short- and long-term symptom and physiologic benefit. Predictors of favorable clinical response to PD include the following: older age (>45 years), female sex, narrow (nondilated) esophagus, and LES pressure after PD of < 10 mm Hg (54–58). Thus, serial dilation starting with the 3.0-cm balloon first may not be effective in younger men (age <45 years), possibly because of thicker LES musculature. In this group of younger men, PD starting at 3.5 cm, in addition to LHM or POEM, may be considered initial treatment approaches.

The most serious complication associated with PD is esophageal perforation with an overall median rate in experienced hands (>100 patients treated) of 1.9% (range 0%–16%) (55,59). Every patient undergoing PD must be aware of the risk and understand that surgical intervention is possible in the event of perforation. Early recognition and management of perforation is key to better patient outcomes. Conservative therapy with antibiotic, parenteral nutrition, and stent placement may be effective in small perforation, but surgical repair through thoracotomy is the best approach in large and extensive mediastinal contamination. GERD may occur after PD in 15%–35% of patients, and in the case of recurrent dysphagia, GERD-related distal esophageal stricture should be considered a potential contributing complication. Thus, PPI therapy is indicated in those with GERD after PD.



**Figure 4.** (a) Fluoroscopic image of using a 3.0-cm pneumatic dilator in a patient with achalasia showing balloon positioning of 2 rings (middle of balloon; blue arrow) at the esophagogastric junction with subsequent dilation to obliterate the balloon waist. (b) Pneumatic dilation via direct endoscopic approach showing positioning of the 2 rings at the esophagogastric junction during endoscopy with inflation of the balloon to the maximum pressure of 13 mm Hg.

Currently, there is no standardized protocol for PD, and there is substantial variability in terms of the predilation setup, balloon dilation protocol, and postdilation recovery. One aspect of postdilation management that is associated with significant variability in practice patterns is the utilization of routine postdilation gastrografin esophagram to rule out perforation. This approach is borne out of the fear of missing an esophageal perforation because this could have devastating consequences. However, there is minimal data to support that this approach improves outcome. A recent study by Zori et al. (60) retrospectively assessed 119 achalasia dilations where 49 patients underwent routine esophagram and 70 were observed and did not have routine esophagram. None of the 49 patients who underwent routine esophagram had a perforation and 12 of the 70 patients without routine esophagram in the clinical observation group eventually underwent esophagram because of clinical suspicion. Of these 12, 3 were found to have a perforation, and none of the 58 patients who did not undergo esophagram had a perforation during follow-up. These results support that there is no role for routine esophagram and that this test should be reserved for patients with clinical suspicion of perforation. A similar study assessing routine esophagram after peroral esophageal myotomy (POEM) and another study assessing routine contrast studies after Heller myotomy also questioned the need for routine postintervention follow-up because the esophagram had low specificity for clinically significant complications (61,62).

### Recommendation

6. Based on no evidence to support routine esophagram and the current shift in practice patterns to perform endoscopy after dilation to rule out and potentially treat perforation endoscopically, we do not suggest obtaining routine gastrografin esophagram after dilation.

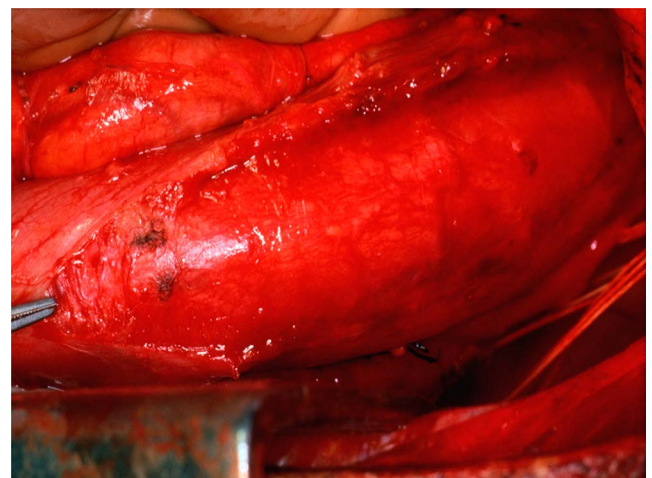
This test should be reserved for patients with a clinical suspicion for perforation after dilation.

### Surgical myotomy

Surgical myotomy is one of the 3 definitive therapies for achalasia. The original approach to surgical myotomy involved division of the muscle fibers of the LES (circular layer without disruption of

the mucosa) through a thoracotomy (63). This achieved good-to-excellent results in 60%–94% of patients followed for 1–36 years (32), and it remained the surgery of choice for many years. The technique evolved initially with a laparotomy approach, which was subsequently supplanted by minimally invasive techniques. A thoracoscopic approach was developed and used with success, but laparoscopic myotomy has become the preferred method because of decreased morbidity and faster recovery (63) (Figure 5).

Studies comparing the effectiveness of surgical modalities in achalasia are not homogeneous in follow-up length and definition of treatment success (48). Furthermore, all of the available literature is based on prospective or retrospective cohort or case-control studies because there are no randomized controlled trials comparing the different approaches with myotomy. In 13 studies of open transthoracic myotomy that included a total of 842 patients, symptom improvement was achieved in a mean 83% of patients (range 64%–97%). For open transabdominal myotomy, symptom improvement was achieved in 85% (range 48%–100%) of 732 patients in 10 studies. Data for thoracoscopic myotomy included 211 patients from 8 studies, with symptom improvement in a mean 78% (range 31%–94%) of patients. Finally, in 39



**Figure 5.** Surgical view of the distal esophagus during a myotomy.



studies of laparoscopic myotomy that included a total of 3,086 patients, symptom improvement was achieved in a mean 89% of patients (range 77%–100%) (48). As with PD, the efficacy of Heller myotomy decreases with longer follow-up periods. In a series of 73 patients treated with Heller myotomy, excellent/good responses were reported in 89% and 57% of patients at 6-month and 6-year follow-up, respectively (55). In addition, some have suggested that previous PD may result in a higher rate of intraoperative mucosal perforation, but no change in the long-term symptomatic outcome (64). A meta-analysis of 1,575 patients having undergone various treatments for achalasia showed that LHM is successful, but its success rate depends on achalasia subtype. Types I and II achalasia patients did better post-LHM than type III patients with success rates of 81%, 92%, and 71%, respectively (21). Therefore, LHM is an appropriate initial therapy in patients with achalasia who are surgical candidates.

**Fundoplication postmyotomy.** The development of GERD after myotomy is a frequent problem, and whether an antireflux procedure should be performed to prevent reflux has been the subject of extensive debate, especially given concerns for increased postoperative dysphagia after a fundoplication. The average frequencies of GERD postsurgical myotomy without fundoplication for thoracotomy, laparotomy, thoracoscopy, and laparoscopy are similar: 29%, 28%, 28%, and 31%, respectively (48). Adding fundoplication after myotomy decreases the risk of GERD for thoracotomy, laparotomy, and laparoscopy; 14%, 8%, and 9%, respectively. No study has included fundoplication after thoracoscopic myotomy (48). The benefit of adding a fundoplication was demonstrated in a double-blind randomized trial comparing myotomy with vs without fundoplication (65). In this study, abnormal acid exposure on pH monitoring was found in 47% of patients without an antireflux procedure and 9% in patients who had a posterior Dor fundoplication. Heller myotomy with fundoplication was associated with significant risk reduction of GER (relative risk: 0.11; 95% CI: 0.02–0.59). This trial has since published 11-year follow-up data regarding patient-reported symptoms after surgical intervention (66). Patients reported similar long-term outcomes in reflux symptom control for both surgical interventions. Indirect evidence regarding this clinical question comes from a recent meta-analysis comparing POEM and laparoscopic Heller myotomy with fundoplication (67). The study included 1,542 patients who underwent POEM and 2,581 patients treated by Heller myotomy with fundoplication. Distal esophageal acid exposure was higher after POEM compared with laparoscopic myotomy with fundoplication (39.0% vs 16.8%). Abovementioned studies demonstrate that addition of fundoplication to myotomy reduces the incidence of distal esophageal acid exposure. Benefit of fundoplication is sustained long term. The achalasia guidelines from the Society of American Gastrointestinal and Endoscopic Surgeons recommended that patients who undergo myotomy should have a fundoplication to prevent reflux (68). The strength of evidence supporting the recommendation for addition of fundoplication to myotomy is limited by heterogeneity of studies.

### Recommendation

7. Thus, based on available data, we recommend that myotomy with fundoplication is superior to myotomy without fundoplication in controlling distal esophageal acid exposure.

**Dor and Toupet antireflux procedure after myotomy.** Although it has been fairly well established that adding a fundoplication is beneficial for reducing the rate of GERD after myotomy, there is less certainty on the best approach (anterior Dor or posterior Toupet). A multicenter randomized controlled trial comparing these 2 approaches found a nonsignificant higher percentage of abnormal pH test results in 24 patients with Dor compared with 19 patients with Toupet fundoplication (41% vs 21%) with similar improvement of dysphagia and regurgitation symptoms in both groups (69). Metaregression of randomized trials comparing 2 different antireflux procedures performed in addition to surgical myotomy found that the odds of an abnormal postoperative 24-hour pH study result were 0.16 (95% CI, 0.11–0.24) for myotomy with anterior fundoplication and 0.18 (95% CI, 0.13–0.25) for myotomy with posterior fundoplication (70). Acid exposure was not significantly different after anterior and posterior approaches to fundoplication. Dysphagia and reintervention rates were significantly lower for myotomy with posterior fundoplication compared with anterior fundoplication. A recent update to this meta-analysis suggested Toupet fundoplication to be superior to Dor for length of hospital stay and patient quality of life, whereas other measured variables of postoperative GERD, dysphagia, or complication rates and treatment failure were equivalent (71).

### Recommendation

8. Therefore, based on current data, we suggest either Dor or Toupet fundoplication to control esophageal acid exposure in patients with achalasia undergoing surgical myotomy.

### Peroral endoscopic myotomy

Although the current treatments for achalasia are effective, PD is associated with a perforation risk of 1.9% (72), and myotomy still requires laparoscopy and dissection of the EGJ. Thus, a hybrid technique was developed to incorporate an endoscopic approach with principles of natural orifice transluminal endoscopic surgery to perform a myotomy. This technique was developed in Japan and is termed peroral endoscopic myotomy or POEM (73). The procedure requires the creation of a submucosal plane using a forward viewing endoscope with a distal transparent cap to access the circular muscle fibers for performance of the myotomy. An endoscopic submucosal dissection knife is used to dissect the plane and also cut the muscle over a minimum length 6 cm into the esophagus and 2 cm below the squamocolumnar junction onto the cardia. Overall, the success rate, defined by an improvement in symptoms and no requirement of additional medical or surgical treatment, in prospective cohorts has been greater than 90% (74–77), and this does seem to have promise as an alternative to the laparoscopic approach.

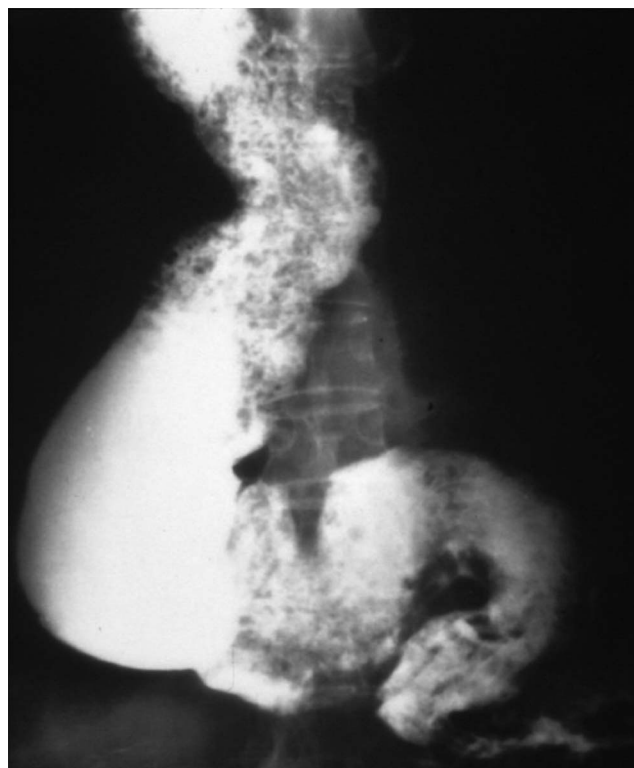
One of the most commonly used areas in achalasia for POEM has been its use in type III achalasia. Patients with type III achalasia exhibit obstructive contractility of the distal esophagus and have been noted to have less of a response to disruptive therapies to the LES (Heller myotomy or PD) than those with type I or type II achalasia. One benefit of POEM involves the fact that the length of the myotomy can be tailored with the potential to include the length of the entire smooth muscle of the esophagus if necessary. This length can be tailored to findings of the length of the spastic segment noted on high-resolution esophageal manometry, length of esophageal wall thickening noted on EUS, or FLIP.

A 2013 study assessed whether manometric subtype was associated with response to treatment in patients treated with either PD or LHM as part of the European achalasia trial. Eighteen patients had type III achalasia in the study. These patients had a higher success rate with LHM compared with PD (86% vs 40%,  $P = 0.12$ ); the authors noted that the difference was not statistically significant because of the small number of patients (16). A 2019 meta-analysis of clinical outcomes after treatment for achalasia based on achalasia subtype found that success rates for LHM in type III achalasia were 71%, compared with 93% for POEM. POEM was more likely to be successful than LHM for patients with type III achalasia (odds ratio [OR] 3.50, 1.39–8.77;  $P = 0.007$ ) (21). One retrospective study comparing 49 patients who underwent POEM for type III achalasia with 26 patients who underwent LHM found that those who underwent POEM had an improved clinical response (98.0% vs 80.8%,  $P = 0.01$ ), shorter mean procedure time, and lower rate of adverse events (6% vs 27%,  $P < 0.01$ ) (27). A 2017 systematic review and meta-analysis found that for 116 patients studied with type III achalasia, the weighted pool rate for clinical success of POEM was 92%. The weighted pooled rate for post-procedure adverse events was 11% (78). A 2017 study reported the outcomes of 32 patients with type III achalasia who underwent POEM at a single center. After a median follow-up of 27 months, 90.6% of patients achieved symptom relief, with mean ES pretreatment of 7.2 and post-treatment of 1.4 ( $P < 0.001$ ). Mean LES pressure decreased from mean of 39.2 to 19.0 mm Hg after the procedure ( $P < 0.002$ ). Complication rates of GERD were 18.8% after POEM (26). The authors of the 2019 randomized controlled trial comparing PD and POEM noted that the effect of POEM and PD on treatment outcome was not related to achalasia subtype (including for type III achalasia); however, this study may have been underpowered to detect a difference (79).

### Recommendation

9. Thus, based on current data, we recommend tailored POEM or LHM for type III achalasia as a more efficacious disruptive therapy of the LES compared with PD.

GERD post-POEM has been the issue in tempering stronger recommendations for embracing POEM in many centers. The recent 2019 randomized controlled trial (RCT) comparing PD and POEM noted that 2 years after undergoing intervention for achalasia, 41% of those in the POEM group were found to have esophagitis at the time of endoscopy compared with 7% in the PD group ( $P = 0.002$ ); note that PPI use was not withheld at the 2-year mark at the time of endoscopy in those patients requiring PPI use (79). Nonrandomized observational studies have shown post-treatment reflux in up to 58% of patients undergoing POEM (80) compared with only 15%–35% of patients who undergo PD (1). A 2018 systematic review and meta-analysis found a high incidence of reflux in those undergoing POEM compared with surgical myotomy (OR 9.31 for erosive esophagitis, 1.69 for symptomatic GERD, and 4.30 for GERD noted on pH monitoring) (81). A separate 2018 systematic review and meta-analysis (67) found a pooled rate estimate of abnormal acid exposure at pH monitoring of 39.0% (95% CI, 24.5%–55.8%) after POEM compared with 16.8% (95% CI, 10.2%–26.4%) after surgical myotomy. They noted a rate of esophagitis of 29.4% (95% CI, 18.5%–43.3%) after



**Figure 6.** Dilated sigmoid esophagus representing end-stage achalasia with retained saliva and barium.

POEM compared with 7.6% (95% CI, 4.1%–13.7%) after surgical myotomy.

### Recommendation

10. We support the evidence that in patients with achalasia, POEM compared with LHM with fundoplication or PD is associated with a higher incidence of GERD.

It may be prudent to screen patients who undergo POEM for erosive esophagitis or Barrett's esophagus, and patients who are contemplating POEM should be advised that lifelong acid suppression with PPIs may potentially be needed (82).

### Esophagectomy

In the setting of poor esophageal emptying and high LES pressure, esophageal diameter can increase, and some patients may develop “end-stage” achalasia characterized by megaesophagus or sigmoid esophagus and significant esophageal dilation and tortuosity (Figure 6). This group of patients and those with untreated achalasia are at risk of aspiration, aspiration pneumonia, and malnutrition. In this group of patients, PD, surgical myotomy, or POEM may be less effective, and those with compromised nutrition may require enteral feeding. Endoscopic myotomy has been associated with a 2-fold increase in the risk of periprocedural complications in patients with sigmoid esophagus (83). Data regarding outcomes of esophagectomy for end-stage achalasia comes from observational and cohort studies because no randomized trials were published on this topic. A recently conducted meta-analysis looked at the outcomes of esophagectomy in advanced achalasia but did not include direct comparisons with

endoscopic or surgical myotomy, account for natural disease history, age at onset of achalasia, time elapsed to reach the end-stage disease phenotype, or specify the number and type of previous treatment interventions (84). Esophagectomy was associated with high incidence of postoperative respiratory complications including pneumonia (10%, 95% CI: 4%–18%), but the intervention showed reasonably low mortality in carefully selected individuals treated at highly specialized surgical centers (2%, 95% CI: 1%–3%).

### Recommendation

- Therefore, based on these limited data, we recommend esophagectomy in surgically-fit patients with megaesophagus who have failed other interventions.

No recommendations can be made regarding type of surgical approach and esophageal substitute (stomach vs colon) because of the small number of subjects included in existing studies and their significant heterogeneity. However, an extensive review on this topic found that gastric interposition is the first choice of therapy in most patients undergoing esophagectomy (85).

### Self-expanding stents

There is a small body of low-quality evidence supporting the use of self-expanding metallic stents (SEMS) as effective treatment for achalasia (86–88). Thirty millimeter temporary SEMS seemed to have superior long-term clinical efficacy in patients with achalasia compared with 20- and 25-mm stents. Higher symptom remission rates were seen for subjects treated with metal stents compared with botulinum toxin injection (49.1% vs 4.2%) as assessed after a 36-month follow-up period (87). Botulinum toxin injection was not associated with any complications, but individuals treated by SEMS reported chest pain and regurgitation. Stent migration was relatively rare, likely because of baseline esophageal aperistalsis that is observed in patients with achalasia. The primary limitation for use of SEMS in achalasia stems from the fact that this intervention is a temporary measure which does not provide definitive treatment. Furthermore, SEMS used in the study by Dai et al. (87) were highly specialized, and they are not widely available outside of China. To date, limited available data do not support the routine use of stents in long-term symptom management of patients with achalasia.

### Recommendation

- Despite low-quality data, we recommend against stent placement for the management of long-term dysphagia in patients with achalasia.

### Comparative effectiveness of therapeutic modalities

**PD vs medical therapy.** There are no head-to-head comparison studies of most pharmacotherapy agents and other more definite therapies of PD, LHM, or POEM. Most studies with these agents are either case series or case control designed studies with only a few randomized trials comparing their efficacy with placebo. Only 1 prospective observational study compared dilation with less effective Rider-Moeller dilators to sublingual nifedipine showing similar efficacy (37). Despite the lack of comparative trials and based on many studies using the more definitive therapies in achalasia, it is generally accepted that pharmacotherapy is

less effective, given shorter duration of action, poor benefit in esophageal emptying, and symptom relief in achalasia (32).

### Recommendation

- We recommend that PD is superior to medical therapy in relieving symptoms and physiologic parameters of esophageal emptying.

Medical therapy is thus recommended only for patients with achalasia who are not candidates for definitive therapies of PD, LHM, or POEM.

**PD vs endoscopic Botulinum toxin injection.** Randomized controlled trials have compared the effectiveness of these 2 treatment options in achalasia. For instance, a study of 42 patients who were randomized to botulinum toxin or graded PD with 30 and 35 mm Rigiflex balloons reported success of 70% for PD and 32% for botulinum toxin injection at 12 months (89). A recent Cochrane database review of 7 studies involving 178 patients found no significant difference in remission between PD or botulinum toxin within 4 weeks of the initial intervention (90). Three studies included in the review had 12-month data with remission in 55 of 75 PD patients compared with 27 of 72 botulinum toxin–treated patients (relative risk of 1.88, 95% CI: 1.35–2.61). These results provide strong evidence that PD is more effective than botulinum toxin in the long term for patients with achalasia. Therefore, we recommend PD is superior to botulinum toxin injection in long-term relief of symptoms and physiologic parameters in patients with achalasia.

**PD vs LHM.** PD and LHM are both excellent treatment options in patients with achalasia (1,32). They both demand that the patients' comorbidities (not age) are permissive for such interventions. Several observational studies have shown success rates ranging from 80% to 95% for PD and similar rates of more than 80% success reported for LHM (55,91–105). A European randomized controlled trial comparing the 2 interventions in 201 patients with achalasia showed similar efficacy at 2 years (86% vs 90%,  $P = 0.3$ ) and 5 years (84% and 82%,  $P = 0.9$ ) for PD and LHM, respectively (54,106). In addition, long-term–related quality-of-life outcomes among those undergoing PD or LHM were shown to be similar at 5.7 years after therapy among patients with achalasia (107). A randomized multicenter Canadian study recently showed that there was no significant difference in achalasia-specific quality of life between the 2 treatment strategies assessed at 5 years (104).

### Recommendation

- We recommend that PD or LHM are both effective and equivalent short- and long-term procedures for patients with achalasia who are candidates to undergo definitive therapy.

**PD vs POEM.** The only randomized controlled trial comparing POEM and PD was recently published by Ponds et al. (79) and evaluated 133 adults with treatment-naïve achalasia undergoing treatment at 6 centers. This is the first RCT to evaluate POEM as a first-line treatment for achalasia. After 2 years of follow-up, the success rate (as defined by  $ES \leq 3$  and without serious adverse event) was 92% after POEM compared with 54% after PD ( $P < 0.001$ ). There was 1 perforation after PD (rate 1.5%), and no serious adverse events with POEM.

These results are incongruous with the findings of the RCT published in 2015 comparing long-term outcomes of PD vs LHM that showed greater treatment success with PD than depicted in the Ponds study (54). This is because of differences in the study design. The study by Ponds et al. limited PD to 1 or 2 dilations with 30- or 35-mm balloons, with the second dilation permitted if the ES was  $\geq 3$  or if manometry noted an integrated relaxation pressure  $>10$  mm Hg. Previous studies showing success rates of PD of 85%–90% after follow-up of 2–5 years permitted dilation sequentially from 30- to 40-mm balloon sizes until sufficient symptom response was attained. The Ponds study reported a post hoc analysis with findings of a 76% PD success rate if the 14 patients who did undergo an additional PD to 40 mm were included.

A 2017 retrospective study at one center in China included 32 patients who underwent POEM and 40 who underwent PD (20). On the short-term follow-up, similar improvements were noted in manometry and esophagram parameters. Patients were followed for up to 36 months. For PD, the success rate at 3 months was 95% and at 36 months was 60%. For POEM, the success rate at 3 months was 96% and at 36 months was 93%. ( $P = 0.013$ , log-rank test). Based on subgroup analysis, the success rate was higher with POEM compared with PD for all 3 manometric subtypes of achalasia; however, this was only statistically significant for patients with type III achalasia. POEM required significantly longer operative time and hospitalization ( $P < 0.001$ ) and 4 patients undergoing POEM experienced subcutaneous emphysema. A 2016 retrospective chart review of 200 patients with achalasia at the Cleveland Clinic found that at 2 months post-treatment, when the efficacy of 3 treatments (POEM, PD, and LHM) were compared for improvement of esophagram or esophageal manometry parameters, there was no significant difference in efficacy among the 3 treatment options ( $P > 0.05$ ) (108).

### Recommendation

15. We recommend that POEM or PD result in comparable symptomatic improvement in patients with types I or II achalasia.

The choice of treatment modality depends on institutional strength and patient preference.

**LHM vs botulinum toxin injection.** Zaninnoto et al. (109) published a randomized controlled trial directly comparing surgical myotomy with sequential botulinum toxin injections spaced 1 month apart. A dose of 8 to 100 U of botulinum toxin was used for treatment. Eighty patients were involved in the study: 40 received botulinum toxin and 40 underwent laparoscopic myotomy. Six months after treatment, symptom improvement was better for the surgical myotomy group compared with patients treated by botulinum toxin (82%, 95% CI: 76%–89% vs 66%, 95% CI: 57%–75%,  $P \leq 0.05$ ). Symptoms recurred in 65% of patients treated with botulinum toxin; the probability of being symptom free at 2 years was 87.5% for surgical myotomy and 34% for botulinum toxin. Economic analysis published for a subset of the patients involved in this trial showed that the initial cost of botulinum toxin was lower but when treatment effectiveness at 2 years was considered, the cost savings associated with botulinum toxin dissipated (110). In a systematic review on surgical vs endoscopic therapy

(botulinum toxin) for achalasia, outcomes of 7,855 patients with achalasia from 105 studies were analyzed (48). Studies using open and minimally invasive myotomy were included. Authors demonstrated that laparoscopic myotomy combined with an antireflux procedure provided symptom relief in 90.3% of patients (77%–100%) with a low complication rate (6.3%). Therefore, we recommend LHM over botulinum toxin injection in patients with achalasia fit for surgery.

**LHM vs POEM.** One randomized controlled trial was recently published comparing POEM with surgical myotomy showing noninferiority of POEM to LHM (111). In this study, the authors randomly assigned patients with achalasia to either POEM (112 patients) or LHM plus Dor fundoplication (109 patients). Clinical success at 2 years after intervention was 83% for POEM and 82% for LHM. A 2018 systematic review and meta-analysis compared outcomes among 1,958 patients undergoing POEM and 5,834 patients undergoing surgical myotomy and found that at 12 months after treatment, predicted probabilities for improvement in dysphagia were 93.5% for POEM and 91.0% for surgical myotomy ( $P = 0.01$ ), and at 24 months after treatment were 92.7% for POEM and 90.0% for LHM ( $P = 0.01$ ) (81). A 2017 systematic review and meta-analysis found a significantly higher short-term clinical treatment failure rate for surgical myotomy (OR 9.82; 95% CI, 2.06–46.80,  $P < 0.01$ ) (112). No significant difference was found in operative time, complication rate, or length of hospital stay between the 2 treatment modalities. There are several nonrandomized studies that have compared POEM and surgical myotomy (113–116). These studies illustrate similar outcomes to somewhat of an advantage in efficacy for POEM over surgical myotomy; in some studies, however, metrics assessed and duration of treatment response measured vary. Long-term, randomized studies are needed to compare these treatment modalities.

### Recommendation

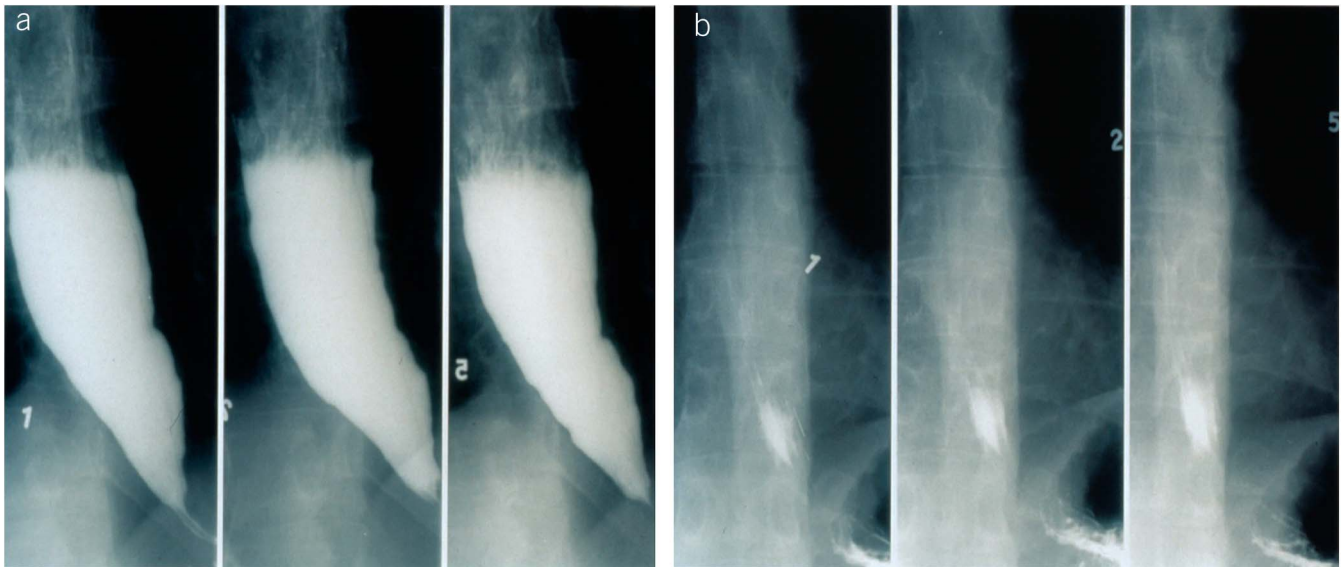
16. We recommend that POEM and LHM result in comparable symptomatic improvement in patients with achalasia.

### POST-THERAPY ASSESSMENT

Treatment failure is typically determined by the recurrence of symptoms typically measured by the symptom score using the ES; however, this approach has been questioned in the era of patient-reported outcome (PRO) development, and the findings that bolus retention post-treatment has some degree of discordance with the ES (117,118). The cause for continued or recurrent symptoms in patients with achalasia after definitive therapy may be related to incomplete disruption of the LES (myotomy and dilation), anatomical distortion related to dilatation, tortuosity, diverticulum formation, GERD, and presence of spastic contractions (119).

### Eckardt score

The ES is a simple metric designed to follow outcomes after achalasia intervention and currently is the standard metric used in almost all treatment trials (91,106). The widespread utilization of this tool was based on expert opinion, and over the past decade, the ES has been preferred over the Vantrappen classification and the Modified Achalasia Dysphagia Score (120,121). The score focuses on the 3 main symptoms associated with achalasia—dysphagia, regurgitation, and chest pain—and also assesses



**Figure 7.** Timed barium swallow (a) before and (b) after pneumatic dilation showing retention of barium in the former and complete emptying posteffective therapy.

weight loss as a marker of the ability for the patient to maintain nutrition. Each of the 4 components are equally weighted and scored from 0 to 3 for a cumulative range of 0–12, and a threshold value of greater than 3 is considered to be a suboptimal outcome (122). Most treatment studies show that the ES will improve after intervention, and higher scores after intervention are associated with more symptoms and the likelihood to proceed with repeat intervention. Unfortunately, the ES was developed before the defined criteria for a PRO were developed by the FDA that supported a 3-step procedure to adequately validate a PRO for treatment trials as follows: (i) initial patient interviews/focus groups to generate scale items, (ii) administering the scale to a large and representative sample of patients, and (iii) reviewing the scale items via structured cognitive interviews with an additional small cohort of target patients. Recently, Taft et al. (123) systematically assessed the factor structure, reliability, and construct validity of the ES and concluded that this score performed at a marginal level for reliability and validity and that most of the score could be explained by the dysphagia component alone. This study also suggested that the chest pain and weight loss component were decreasing the performance of the ES. Based on these results, it seems that the ES alone is not sufficient to follow treatment success and define failure. Thus, assessment of treatment failure should be revisited and may require development of a new PRO.

### High-resolution manometry

Although the symptom type will likely guide clinical judgement, it may be difficult to determine which of these causes are affecting the patient, and thus, further diagnostic testing is warranted outside of instances where the patient has heartburn and a PPI trial is attempted. High-resolution manometry can assess the completeness of myotomy and also determine whether spastic contractions are present after treatment; however, it is unable to determine bolus retention accurately, assess the contribution of GERD, and the procedure may be difficult because of obstruction and abnormal anatomy.

### Timed barium esophagram

Timed barium esophagram (TBE) (Figure 7) can determine whether there is bolus retention, and it can be enhanced with a barium tablet to determine whether retention is related to obstruction at the EGJ or potentially distorted anatomy. TBE is an important tool in the diagnosis of achalasia and post-therapy assessment of treatment success (116,117). Before therapy, most patients have retained barium at 1-, 2-, and 5-minutes after the ingestion of a large barium bolus (Figure 7a) which after successful intervention TBE is expected to show complete esophageal emptying at 1-minute post-ingestion (Figure 7b). Overall, there are no studies that compare HRM with TBE head to head in assessing treatment failures in achalasia in a random controlled design. Most studies are blinded comparator studies assessing the predictive value of HRM or new impedance and FLIP measures vs TBE using the ES as the outcome of interest (29,124). These studies have suggested that barium esophagram after intervention is a useful tool to assess outcome and requirement for therapy (117,125,126); however, there are also other studies that argue against this predictive value (127,128). The data are poor regarding HRM as a predictive tool in assessing treatment failure and prognostic requirements of repeat intervention.

### Recommendation

17. In conclusion, we recommend that ES or HRM alone not be used to define treatment failure. We recommend using TBE as the first-line test in evaluating continued or recurrent symptoms after definitive therapy for achalasia.

Patients with recurrent symptoms should be evaluated with objective testing, and patients with improvement in symptoms and continued evidence of retention (barium column > 5 cm at 5 minutes) should be followed closely and potentially offered treatment if retention worsens or dilatation increases.

## MANAGEMENT OF FAILED THERAPY OR RECURRENT DISEASE

### PD after initial LHM or POEM

The failure rate for Heller myotomy and POEM over 1–3 years can be anywhere from 5% to 30% and higher when follow-up is extended to 10 years and beyond. The mechanism for failure of myotomy during Heller myotomy and POEM can be related to an incomplete myotomy, scarring, and other factors related to anatomical distortion. Post-fundoplication issues may arise with Heller myotomy when an antireflux surgery is added to the operation, and this can be related to a tight wrap or herniation. PD is an attractive treatment for myotomy failures because it spares the patient another more invasive procedure and can address an incomplete myotomy, scarring, and a tight fundoplication. Whether this approach is superior or equal to redo myotomy with either a redo-Heller myotomy or a redo-POEM is unclear because there are no randomized or controlled studies assessing these different approaches in patients with myotomy failure. In patients who have failed definitive therapy with LHM or POEM who continue to be candidates for repeat intervention, all 3 options of PD, LHM, and POEM are reasonable approaches. Given previous interventions with LHM or POEM, the question of safety of PD in this group is often raised. Based on retrospective observational studies (129–133) and 1 systematic review (134), PD seems to be safe and effective. In the systematic review, 87 patients post failed LHM underwent repeat treatment with PD. The mean number of pneumatic dilations performed in this group was 2.5 (range 1–3) with mean interval between dilations of 26 months (range: 0–144). The success rate with PD in this group was 89%, and reported complications related with PD was extremely low. Thus, PD could be an effective therapy in those with failed LHM. Reports on PD post-POEM are scarce, but based on retrospective observational studies (135,136), PD seems to be safe if patients fail POEM as the initial definitive therapy. Future larger scale data are needed in this group, but given the long-term experience for those who failed LHM, we expect that PD would continue to be a robust option in this difficult group of patients.

### Recommendation

18. We recommend that PD is an appropriate and safe treatment option for patients with achalasia postinitial surgical myotomy or POEM in need of retreatment.

### LHM after PD or POEM

Many patients with refractory achalasia or end-stage achalasia defined by barium esophagram features of severe dilatation (width > 6 cm) and complicated anatomical distortion (sink-trap) have severe symptoms and life-threatening complications, and thus, action must be taken to avoid aspiration, malnutrition, and death (85). Unfortunately, esophagectomy is associated with a high rate of complications and a real risk of death (84,137). In addition, quality of life after esophagectomy is diminished, and thus, this approach should be considered a last resort, and most patients and physicians would prefer an attempt at more conservative treatment. For patients who have failed PD and POEM, it may still be reasonable to attempt Heller myotomy before referral for esophagectomy based on a case series where patients with severe end-stage disease may respond to surgery (135,138–140). One must realize that the success rate is still much lower than in patients with more favorable anatomy and no previous definitive therapy. A

thorough workup comprising an assessment of anatomy with barium esophagram, upper endoscopy to assess esophagitis and stricture, and potentially manometry or FLIP to assess LES function may provide evidence that targeted therapy at the LES may be effective. Patients with severe anatomy, significant bolus retention, and evidence of a complete myotomy could be referred for esophagectomy, whereas patients with evidence of incomplete myotomy may be offered Heller myotomy. In the end, this decision is extremely difficult, and the approach will require a comprehensive evaluation and an informed discussion focused on the risks and benefits. Patients who require esophagectomy should be referred to high-volume referral centers because outcomes are directly related to volume and expertise.

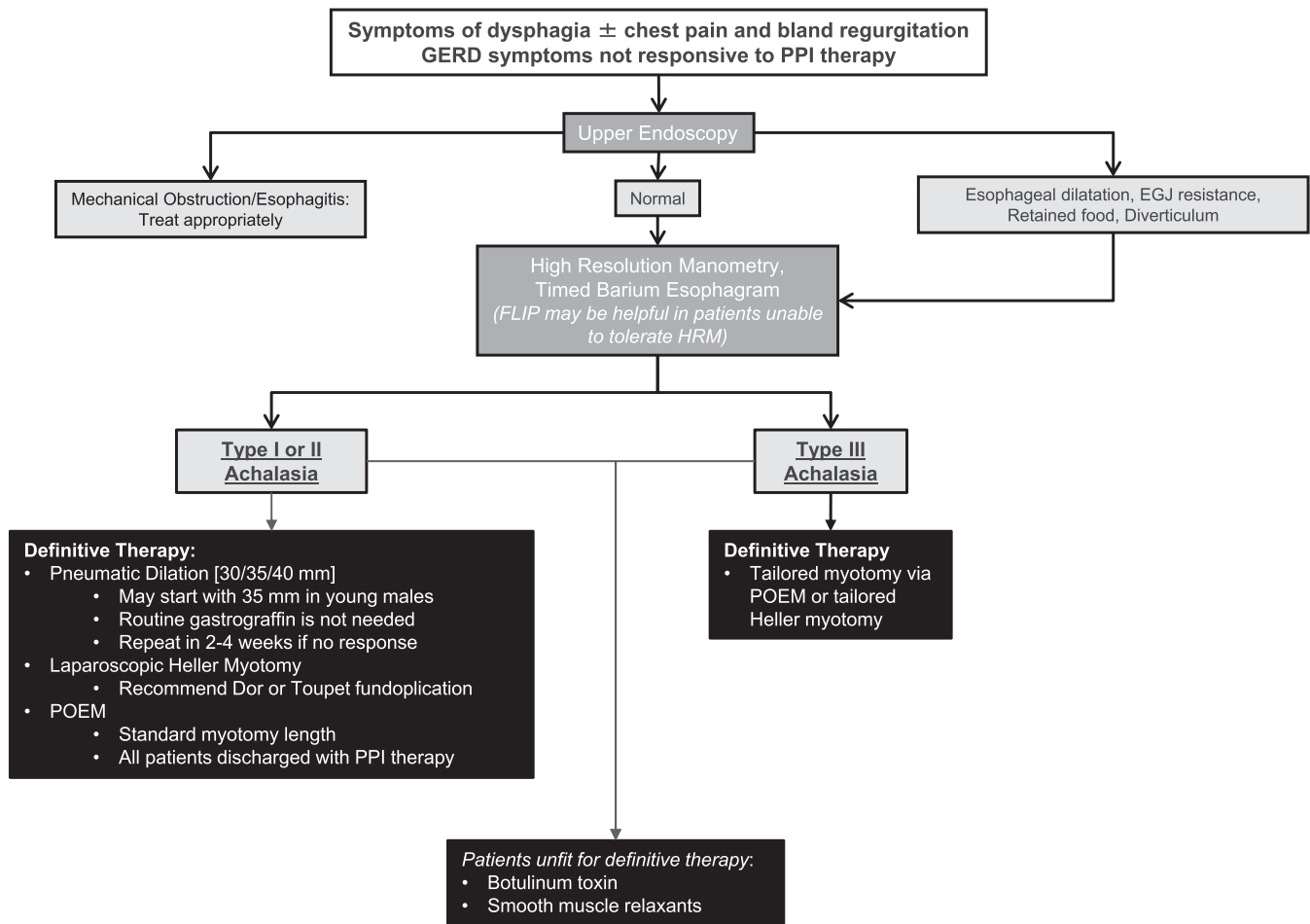
### Recommendation

19. We recommend that Heller myotomy be considered before esophagectomy in patients who have failed PD and POEM if the anatomy is conducive and there is evidence of incomplete myotomy.

This recommendation is based primarily on the morbidity and mortality of esophagectomy and is only supported by small case series in heterogeneous patient populations.

### POEM after PD or LHM

There are limited data available regarding how to treat patients with recurrent symptoms of achalasia who have previously undergone PD or LHM. Tyberg and colleagues published the results of a prospective registry of patients from 13 centers, of which 51 patients had previously undergone LHM and subsequently underwent POEM (141). Mean time between LHM and POEM was 9.5 years (range 2 months–56 years). Ninety-four percent of these patients were reported to have achieved clinical success as defined by an ES of  $\leq 3$  on the 12-month follow-up, with a mean change of ES of 6.25. Seven of these patients had adverse events with 2 with mediastinitis treated conservatively and 6 with a periprocedural mucosal defect treated endoscopically. This study showed that POEM as salvage therapy for recurrent symptoms after previous LHM has been shown to have good short-term efficacy. A retrospective cohort study published in 2017 incorporated 90 patients with achalasia who had previously undergone Heller myotomy compared to 90 patients with achalasia who had not undergone Heller myotomy (142). Median follow-up time was 8.5 months. The definition of clinical response was a decrease in ES to  $\leq 3$ . The authors found that a significantly lower proportion of patients in the Heller myotomy group had a clinical response to subsequent POEM (81%) than those who had not previously undergone LHM (94%;  $P = 0.01$ ). No significant difference was noted regarding the rate of adverse events or symptomatic reflux/reflux esophagitis between the 2 groups. A 2018 study collected data regarding patients with achalasia who underwent treatment at one center (143). Forty-six patients had undergone previous LHM and later underwent POEM as salvage therapy. Among these patients, no clinically significant adverse events took place. Clinical success (defined by ES  $\leq 3$  and no additional treatment needed) was 95.7% at a median follow-up of 28 months. A study of 21 patients after failed PD showed significant improvement in barium height, ES, and LES pressure after POEM (144). In addition, a study of 22 patients with previously



**Figure 8.** Diagnostic and treatment algorithm for patients with suspected achalasia. FLIP, functional lumen imaging probe; GERD, gastroesophageal reflux disease; HRM, high resolution manometry; PPI, proton pump inhibitor.

failed endoscopic dilations showed significant symptom and objective improvements in esophageal parameters after POEM (145).

### Recommendation

20. We recommend that POEM is a safe option in patients with achalasia who have previously undergone PD or LHM.

### Endoscopic surveillance for cancer

The risk of esophageal squamous cell carcinoma is significantly increased in achalasia, and the estimated incidence rate is approximately 1 cancer per 300 patient years. This represents a hazard ratio of 28 for developing esophageal squamous cell carcinoma (146). A recent population-based case control study assessed 7,487 patients in the United Kingdom diagnosed with and receiving a treatment for achalasia between 2000 and 2012 and found that 1.3% of patients developed esophageal cancer (either squamous cell carcinoma or adenocarcinoma) during that time, with an incidence of esophageal cancer of 205 cases per 100,000 patient years at risk (147). This risk was associated with increasing patient age and need for reintervention after primary achalasia treatment. A 2017 systematic review and meta-analysis reported a higher incidence of 312.4 cases per 100,000 patient years at risk for squamous cell carcinoma and 21.23 cases per

100,000 patient years at risk for adenocarcinoma (148). There is evidence that the risk of esophageal adenocarcinoma is also increased in achalasia; however, this is substantially lower than the risk for squamous cell carcinoma. The presumed mechanism for esophageal malignancy in achalasia is because of poor esophageal emptying, with resultant stasis and inflammation leading to dysplasia and the development of esophageal carcinoma. Despite these risks, there are limited data to support routine screening for cancer in patients with achalasia. The overall number of cancers remains low, and estimates have suggested that over 400 endoscopies would be required to detect one cancer (149). These numbers are further tempered by the fact that the survival of these patients is poor, once the diagnosis is made (146). Thus, the most recent American Society of Gastrointestinal Endoscopy guidelines report that surveillance strategies have failed to demonstrate improved survival and cannot be recommended based on current evidence (150).

However, there may be additional benefits to surveillance beyond the cancer risk that may make endoscopic surveillance reasonable. For instance, patients with achalasia are still at risk of progression to megaesophagus, and following symptoms may not be sufficient to determine whether patients may be at risk for disease progression. Given these issues and the lack of a good predictive biomarker, many experts are in favor of some form of endoscopic or radiographic surveillance in patients with achalasia

at an interval of every 3 years if the disease has been present for more than 10–15 years (151). However, further studies are required to determine whether surveillance strategies with defined intervals or new endoscopic techniques will improve overall outcomes.

### Recommendation

21. We recommend against routine endoscopic surveillance for esophageal carcinoma in patients with achalasia.

### TREATMENT ALGORITHM

A reasonable tailored treatment algorithm for patients with achalasia and no previous therapy is outlined in Figure 8. Symptomatic patients with suspected achalasia should undergo upper endoscopy to ensure no other pathology and to rule out pseudoachalasia. HRM and timed barium swallow should be used to confirm the diagnosis. The choice between the therapeutic modalities depends on manometric subtypes of achalasia, patient preference, and institutional expertise. PD, HM, and POEM are good choices in those with types I and II achalasia. PD should be performed in a graded fashion starting with the smallest balloon (3.0 cm) except in younger men (less than age 45 years) who may benefit with the initial balloon size of 3.5 cm or surgical myotomy. In patients unresponsive to PD, surgical myotomy should be performed. In patients with type III achalasia tailored HM or POEM may be used. If patients are unfit to undergo definitive therapy because of comorbidities, then therapy with botulinum toxin and smooth muscle relaxants should be offered. To maximize patient outcomes, all definitive therapies should be offered in centers of excellence with adequate volume and expertise. Postintervention patients should be followed for symptom recurrence and complications from GERD. TBE and endoscopy can be complementary in assessing for recurrent disease vs reflux-related inflammation or stricturing. Repeat PD, HM, or POEM may be performed in those with recurrent disease and acid-suppressive therapy should be offered to those with GERD-induced symptoms. Esophagectomy may be needed in those with a dilated esophagus (larger than 8 cm) with poor response to an initial myotomy.

### ACKNOWLEDGMENTS

This guideline was produced in collaboration with the Practice Parameters Committee of the American College of Gastroenterology. The Committee gives special thanks to Amit Patel, MD, who served as guideline monitor for this document.

### CONFLICTS OF INTEREST

**Guarantor of the article:** Michael F. Vaezi, MD, PhD, MSc, FACC.

**Specific author contributions:** All authors contributed to the planning, data analysis, writing, and the final revision of the manuscript.

**Financial support:** J.E.P. receives grant support from National Institutes of Health DK117824 and DK092217. The remaining authors report no funding support.

**Potential competing interests:** J.E.P. serves as a speaker for Ethicon, serves as a speaker and consultant for Diversatek, has stock options for Crospon, and serves as a speaker, consultant, and has a licensing agreement on FLIP with Medtronic. The remaining authors have no conflicts of interest.

### REFERENCES

1. Vaezi MF, Pandolfino JE, Vela MF. ACG clinical guideline: Diagnosis and management of achalasia. *Am J Gastroenterol* 2013;108(8):1238–49; quiz 50.

2. Vaezi MF, Felix VN, Penagini R, et al. Achalasia: From diagnosis to management. *Ann N Y Acad Sci* 2016;1381(1):34–44.
3. Francis DL, Katzka DA. Achalasia: Update on the disease and its treatment. *Gastroenterology* 2010;139(2):369–74.
4. Spechler SJ, Souza RF, Rosenberg SJ, et al. Heartburn in patients with achalasia. *Gut* 1995;37(3):305–8.
5. Singaram C, Sengupta A, Sweet MA, et al. Nitrinergic and peptidergic innervation of the human oesophagus. *Gut* 1994;35(12):1690–6.
6. Park W, Vaezi MF. Etiology and pathogenesis of achalasia: The current understanding. *Am J Gastroenterol* 2005;100(6):1404–14.
7. Mearin F, Mourelle M, Guarner F, et al. Patients with achalasia lack nitric oxide synthase in the gastro-oesophageal junction. *Eur J Clin Invest* 1993;23(11):724–8.
8. Kahrilas PJ, Bredenoord AJ, Fox M, et al. The Chicago classification of esophageal motility disorders, v3.0. *Neurogastroenterol Motil* 2015; 27(2):160–74.
9. Pandolfino JE, Kwiatek MA, Nealis T, et al. Achalasia: A new clinically relevant classification by high-resolution manometry. *Gastroenterology* 2008;135(5):1526–33.
10. Carlson DA, Ravi K, Kahrilas PJ, et al. Diagnosis of esophageal motility disorders: Esophageal pressure topography vs. conventional line tracing. *Am J Gastroenterol* 2015;110(7):967–77; quiz 78.
11. Roman S, Huot L, Zerbib F, et al. High-resolution manometry improves the diagnosis of esophageal motility disorders in patients with dysphagia: A randomized multicenter study. *Am J Gastroenterol* 2016; 111(3):372–80.
12. Hernandez JC, Ratuapli SK, Burdick GE, et al. Interrater and intrarater agreement of the Chicago classification of achalasia subtypes using high-resolution esophageal manometry. *Am J Gastroenterol* 2012;107(2): 207–14.
13. Fox MR, Pandolfino JE, Sweis R, et al. Inter-observer agreement for diagnostic classification of esophageal motility disorders defined in high-resolution manometry. *Dis Esophagus* 2015;28(8):711–9.
14. Singendonk MM, Smits MJ, Heijting IE, et al. Inter- and intrarater reliability of the Chicago classification in pediatric high-resolution esophageal manometry recordings. *Neurogastroenterol Motil* 2015; 27(2):269–76.
15. Pratap N, Kalapala R, Darisetty S, et al. Achalasia cardia subtyping by high-resolution manometry predicts the therapeutic outcome of pneumatic balloon dilatation. *J Neurogastroenterol Motil* 2011;17(1): 48–53.
16. Rohof WO, Salvador R, Annese V, et al. Outcomes of treatment for achalasia depend on manometric subtype. *Gastroenterology* 2013; 144(4):718–25; quiz e13–4.
17. Lee H, Chung H, Lee TH, et al. Therapeutic outcome of achalasia based on high-resolution manometry: A Korean multicenter study. *Am J Ther* 2019;26(4):e452–61.
18. Lee JY, Kim N, Kim SE, et al. Clinical characteristics and treatment outcomes of 3 subtypes of achalasia according to the Chicago classification in a tertiary institute in Korea. *J Neurogastroenterol Motil* 2013;19(4):485–94.
19. Min M, Peng LH, Yang YS, et al. Characteristics of achalasia subtypes in untreated Chinese patients: A high-resolution manometry study. *J Dig Dis* 2012;13(10):504–9.
20. Meng F, Li P, Wang Y, et al. Peroral endoscopic myotomy compared with pneumatic dilation for newly diagnosed achalasia. *Surg Endosc* 2017;31(11):4665–72.
21. Andolfi C, Fisichella PM. Meta-analysis of clinical outcome after treatment for achalasia based on manometric subtypes. *Br J Surg* 2019; 106(4):332–41.
22. Ou YH, Nie XM, Li LF, et al. High-resolution manometric subtypes as a predictive factor for the treatment of achalasia: A meta-analysis and systematic review. *J Dig Dis* 2016;17(4):222–35.
23. Greene CL, Chang EJ, Oh DS, et al. High resolution manometry subclassification of achalasia: Does it really matter? Does achalasia subclassification matter? *Surg Endosc* 2015;29(6):1363–7.
24. Crespin OM, Tatum RP, Xiao K, et al. The relationship between manometric subtype and outcomes of surgical treatment for patients with achalasia: Achalasia: Manometric subtypes. *Surg Endosc* 2017; 31(12):5066–75.
25. Kim WH, Cho JY, Ko WJ, et al. Comparison of the outcomes of peroral endoscopic myotomy for achalasia according to manometric subtype. *Gut Liver* 2017;11(5):642–7.



26. Zhang W, Linghu EQ. Peroral endoscopic myotomy for type III achalasia of Chicago classification: Outcomes with a minimum follow-up of 24 months. *J Gastrointest Surg* 2017;21(5):785–91.
27. Kumbhari V, Tieu AH, Onimaru M, et al. Peroral endoscopic myotomy (POEM) vs laparoscopic Heller myotomy (LHM) for the treatment of type III achalasia in 75 patients: A multicenter comparative study. *Endosc Int Open* 2015;3(3):E195–201.
28. Hirano I, Pandolfino JE, Boeckxstaens GE. Functional lumen imaging probe for the management of esophageal disorders: Expert review from the Clinical Practice Updates Committee of the AGA Institute. *Clin Gastroenterol Hepatol* 2017;15(3):325–34.
29. Carlson DA, Lin Z, Kahrlas PJ, et al. High-resolution impedance manometry metrics of the esophagogastric junction for the assessment of treatment response in achalasia. *Am J Gastroenterol* 2016;111(12):1702–10.
30. Ponds FA, Bredenoord AJ, Kessing BF, et al. Esophagogastric junction distensibility identifies achalasia subgroup with manometrically normal esophagogastric junction relaxation. *Neurogastroenterol Motil* 2017;29(1):e12908.
31. Carlson DA, Kahrlas PJ, Lin Z, et al. Evaluation of esophageal motility utilizing the functional lumen imaging probe. *Am J Gastroenterol* 2016; 111(12):1726–35.
32. Vaezi MF, Richter JE. Current therapies for achalasia: Comparison and efficacy. *J Clin Gastroenterol* 1998;27(1):21–35.
33. Bortolotti M, Labo G. Clinical and manometric effects of nifedipine in patients with esophageal achalasia. *Gastroenterology* 1981;80(1): 39–44.
34. Hongo M, Traube M, McAllister RG Jr, et al. Effects of nifedipine on esophageal motor function in humans: Correlation with plasma nifedipine concentration. *Gastroenterology* 1984;86(1):8–12.
35. Traube M, Dubovik S, Lange RC, et al. The role of nifedipine therapy in achalasia: Results of a randomized, double-blind, placebo-controlled study. *Am J Gastroenterol* 1989;84(10):1259–62.
36. Traube M, Hongo M, Magyar L, et al. Effects of nifedipine in achalasia and in patients with high-amplitude peristaltic esophageal contractions. *JAMA* 1984;252(13):1733–6.
37. Coccia G, Bortolotti M, Michetti P, et al. Prospective clinical and manometric study comparing pneumatic dilatation and sublingual nifedipine in the treatment of oesophageal achalasia. *Gut* 1991;32(6): 604–6.
38. Kikendall JW, Mellow MH. Effect of sublingual nitroglycerin and long-acting nitrate preparations on esophageal motility. *Gastroenterology* 1980;79(4):703–6.
39. Gelfond M, Rozen P, Gilat T. Isosorbide dinitrate and nifedipine treatment of achalasia: A clinical, manometric and radionuclide evaluation. *Gastroenterology* 1982;83(5):963–9.
40. Gelfond M, Rozen P, Keren S, et al. Effect of nitrates on LOS pressure in achalasia: A potential therapeutic aid. *Gut* 1981;22(4):312–8.
41. Wong RK, Maydonovitch C, Garcia JE, et al. The effect of terbutaline sulfate, nitroglycerin, and aminophylline on lower esophageal sphincter pressure and radionuclide esophageal emptying in patients with achalasia. *J Clin Gastroenterol* 1987;9(4):386–9.
42. DiMarino AJ Jr, Cohen S. Effect of an oral beta2-adrenergic agonist on lower esophageal sphincter pressure in normals and in patients with achalasia. *Dig Dis Sci* 1982;27(12):1063–6.
43. Marzio L, Grossi L, DeLaurentis MF, et al. Effect of cimetropium bromide on esophageal motility and transit in patients affected by primary achalasia. *Dig Dis Sci* 1994;39(7):1389–94.
44. Bortolotti M, Mari C, Lopilato C, et al. Effects of sildenafil on esophageal motility of patients with idiopathic achalasia. *Gastroenterology* 2000; 118(2):253–7.
45. Eherer AJ, Schwetz I, Hammer HF, et al. Effect of sildenafil on oesophageal motor function in healthy subjects and patients with oesophageal motor disorders. *Gut* 2002;50(6):758–64.
46. Pasricha PJ, Ravich WJ, Hendrix TR, et al. Intraspinal botulinum toxin for the treatment of achalasia. *N Engl J Med* 1995;332(12):774–8.
47. Hoogerwerf WA, Pasricha PJ. Pharmacologic therapy in treating achalasia. *Gastrointest Endosc Clin N Am*. 2001;11(2):311–24.
48. Campos GM, Vittinghoff E, Rabl C, et al. Endoscopic and surgical treatments for achalasia: A systematic review and meta-analysis. *Ann Surg* 2009;249(1):45–57.
49. Richardson WS, Willis GW, Smith JW. Evaluation of scar formation after botulinum toxin injection or forced balloon dilation to the lower esophageal sphincter. *Surg Endosc* 2003;17(5):696–8.
50. Patti MG, Feo CV, Arcerito M, et al. Effects of previous treatment on results of laparoscopic Heller myotomy for achalasia. *Dig Dis Sci* 1999; 44(11):2270–6.
51. Smith CD, Stival A, Howell DL, et al. Endoscopic therapy for achalasia before Heller myotomy results in worse outcomes than heller myotomy alone. *Ann Surg* 2006;243(5):579–84; discussion 84–6.
52. Jones EL, Meara MP, Pittman MR, et al. Prior treatment does not influence the performance or early outcome of per-oral endoscopic myotomy for achalasia. *Surg Endosc* 2016;30(4):1282–6.
53. Orenstein SB, Raigani S, Wu YV, et al. Peroral endoscopic myotomy (POEM) leads to similar results in patients with and without prior endoscopic or surgical therapy. *Surg Endosc* 2015;29(5):1064–70.
54. Moonen A, Annese V, Belmans A, et al. Long-term results of the European achalasia trial: A multicentre randomised controlled trial comparing pneumatic dilation versus laparoscopic Heller myotomy. *Gut* 2016;65(5):732–9.
55. Vela MF, Richter JE, Khandwala F, et al. The long-term efficacy of pneumatic dilatation and Heller myotomy for the treatment of achalasia. *Clin Gastroenterol Hepatol* 2006;4(5):580–7.
56. Eckardt VF, Aigherr C, Bernhard G. Predictors of outcome in patients with achalasia treated by pneumatic dilation. *Gastroenterology* 1992; 103(6):1732–8.
57. Farhoomand K, Connor JT, Richter JE, et al. Predictors of outcome of pneumatic dilation in achalasia. *Clin Gastroenterol Hepatol* 2004;2(5): 389–94.
58. Alderliesten J, Conchillo JM, Leeuwenburgh I, et al. Predictors for outcome of failure of balloon dilation in patients with achalasia. *Gut* 2011;60(1):10–6.
59. Eckardt VF, Kanzler G, Westermeier T. Complications and their impact after pneumatic dilation for achalasia: Prospective long-term follow-up study. *Gastrointest Endosc* 1997;45(5):349–53.
60. Zori AG, Kirtane TS, Gupte AR, et al. Utility of clinical suspicion and endoscopic re-examination for detection of esophagogastric perforation after pneumatic dilation for achalasia. *Endoscopy* 2016;48(2):128–33.
61. El Khoury R, Teitelbaum EN, Sternbach JM, et al. Evaluation of the need for routine esophagram after peroral endoscopic myotomy (POEM). *Surg Endosc* 2016;30(7):2969–74.
62. Melman L, Quinlan JA, Hall BL, et al. Clinical utility of routine barium esophagram after laparoscopic anterior esophageal myotomy for achalasia. *Surg Endosc* 2009;23(3):606–10.
63. Ali A, Pellegrini CA. Laparoscopic myotomy: Technique and efficacy in treating achalasia. *Gastrointest Endosc Clin N Am*. 2001;11(2):347–58.
64. Morino M, Rebecchi F, Festa V, et al. Preoperative pneumatic dilatation represents a risk factor for laparoscopic Heller myotomy. *Surg Endosc* 1997;11(4):359–61.
65. Richards WO, Torquati A, Holzman MD, et al. Heller myotomy versus Heller myotomy with Dor fundoplication for achalasia: A prospective randomized double-blind clinical trial. *Ann Surg* 2004;240(3):405–12; discussion 12–5.
66. Kummerow Broman K, Phillips SE, Faqih A, et al. Heller myotomy versus Heller myotomy with Dor fundoplication for achalasia: Long-term symptomatic follow-up of a prospective randomized controlled trial. *Surg Endosc* 2018;32(4):1668–74.
67. Repici A, Fuccio L, Maselli R, et al. GERD after per-oral endoscopic myotomy as compared with Heller's myotomy with fundoplication: A systematic review with meta-analysis. *Gastrointest Endosc* 2018;87(4): 934–43.e18.
68. Stefanidis D, Richardson W, Farrell TM, et al. SAGES guidelines for the surgical treatment of esophageal achalasia. *Surg Endosc* 2012;26(2): 296–311.
69. Rawlings A, Soper NJ, Oelschlager B, et al. Laparoscopic Dor versus Toupet fundoplication following Heller myotomy for achalasia: Results of a multicenter, prospective, randomized-controlled trial. *Surg Endosc* 2012;26(1):18–26.
70. Kurian AA, Bhayani N, Sharata A, et al. Partial anterior vs partial posterior fundoplication following transabdominal esophagocardiomyotomy for achalasia of the esophagus: meta-regression of objective postoperative gastroesophageal reflux and dysphagia. *JAMA Surg* 2013;148(1):85–90.
71. Siddaiah-Subramanya M, Yunus RM, Khan S, et al. Anterior Dor or posterior Toupet with Heller myotomy for achalasia cardia: A systematic review and meta-analysis. *World J Surg* 2019;43(6):1563–70.
72. Richter JE. Update on the management of achalasia: Balloons, surgery and drugs. *Expert Rev Gastroenterol Hepatol* 2008;2(3):435–45.

73. Inoue H, Minami H, Kobayashi Y, et al. Peroral endoscopic myotomy (POEM) for esophageal achalasia. *Endoscopy* 2010;42(4):265–71.
74. Inoue H, Kudo SE. [Per-oral endoscopic myotomy (POEM) for 43 consecutive cases of esophageal achalasia]. *Nihon Rinsho* 2010;68(9):1749–52. Japanese.
75. von Renteln D, Inoue H, Minami H, et al. Peroral endoscopic myotomy for the treatment of achalasia: A prospective single center study. *Am J Gastroenterol* 2012;107:411–7.
76. Swanstrom LL, Rieder E, Dunst CM. A stepwise approach and early clinical experience in peroral endoscopic myotomy for the treatment of achalasia and esophageal motility disorders. *J Am Coll Surg* 2011;213(6):751–6.
77. Evensen H, Kristensen V, Larssen L, et al. Outcome of peroral endoscopic myotomy (POEM) in treatment-naive patients. A systematic review. *Scand J Gastroenterol* 2019;54(1):1–7.
78. Khan MA, Kumbhari V, Ngamruengphong S, et al. Is POEM the answer for management of spastic esophageal disorders? A systematic review and meta-analysis. *Dig Dis Sci* 2017;62(1):35–44.
79. Ponds FA, Fockens P, Lei A, et al. Effect of peroral endoscopic myotomy vs pneumatic dilation on symptom severity and treatment outcomes among treatment-naive patients with achalasia: A randomized clinical trial. *JAMA* 2019;322(2):134–44.
80. Kumbhari V, Familiari P, Bjerregaard NC, et al. Gastroesophageal reflux after peroral endoscopic myotomy: A multicenter case-control study. *Endoscopy* 2017;49(7):634–42.
81. Schlottmann F, Lockett DJ, Fine J, et al. Laparoscopic Heller myotomy versus peroral endoscopic myotomy (POEM) for achalasia: A systematic review and meta-analysis. *Ann Surg* 2018;267(3):451–60.
82. Kahrilas PJ, Katzka D, Richter JE. Clinical practice update: The use of per-oral endoscopic myotomy in achalasia: Expert review and best practice advice from the AGA institute. *Gastroenterology* 2017;153(5):1205–11.
83. Ngamruengphong S, Inoue H, Chiu PW, et al. Long-term outcomes of per-oral endoscopic myotomy in patients with achalasia with a minimum follow-up of 2 years: An international multicenter study. *Gastrointest Endosc* 2017;85(5):927–33 e2.
84. Aiolfi A, Asti E, Bonitta G, et al. Esophagectomy for end-stage achalasia: Systematic review and meta-analysis. *World J Surg* 2018;42(5):1469–76.
85. Duranceau A, Liberman M, Martin J, et al. End-stage achalasia. *Dis Esophagus* 2012;25(4):319–30.
86. Cheng YS, Ma F, Li YD, et al. Temporary self-expanding metallic stents for achalasia: A prospective study with a long-term follow-up. *World J Gastroenterol* 2010;16(40):5111–7.
87. Cai XB, Dai YM, Wan XJ, et al. Comparison between botulinum injection and removable covered self-expanding metal stents for the treatment of achalasia. *Dig Dis Sci* 2013;58(7):1960–6.
88. Zhao JG, Li YD, Cheng YS, et al. Long-term safety and outcome of a temporary self-expanding metallic stent for achalasia: A prospective study with a 13-year single-center experience. *Eur Radiol* 2009;19(8):1973–80.
89. Vaezi MF, Richter JE, Wilcox CM, et al. Botulinum toxin versus pneumatic dilatation in the treatment of achalasia: A randomised trial. *Gut* 1999;44(2):231–9.
90. Leyden JE, Moss AC, MacMathuna P. Endoscopic pneumatic dilation versus botulinum toxin injection in the management of primary achalasia. *Cochrane Database Syst Rev* 2014(12):CD005046.
91. Richter JE, Boeckxstaens GE. Management of achalasia: Surgery or pneumatic dilation. *Gut* 2011;60(6):869–76.
92. Zerbib F, Thetiot V, Richy F, et al. Repeated pneumatic dilations as long-term maintenance therapy for esophageal achalasia. *Am J Gastroenterol* 2006;101(4):692–7.
93. Bravi I, Nicita MT, Duca P, et al. A pneumatic dilation strategy in achalasia: Prospective outcome and effects on oesophageal motor function in the long term. *Aliment Pharmacol Ther* 2010;31(6):658–65.
94. Hulselmans M, Vanuytsel T, Degreef T, et al. Long-term outcome of pneumatic dilation in the treatment of achalasia. *Clin Gastroenterol Hepatol* 2010;8(1):30–5.
95. Costantini M, Zaninotto G, Guirrola E, et al. The laparoscopic Heller-Dor operation remains an effective treatment for esophageal achalasia at a minimum 6-year follow-up. *Surg Endosc* 2005;19(3):345–51.
96. Chen Z, Bessell JR, Chew A, et al. Laparoscopic cardiomyotomy for achalasia: Clinical outcomes beyond 5 years. *J Gastrointest Surg* 2010;14(4):594–600.
97. Kostic S, Kjellin A, Ruth M, et al. Pneumatic dilatation or laparoscopic cardiomyotomy in the management of newly diagnosed idiopathic achalasia. Results of a randomized controlled trial. *World J Surg* 2007;31(3):470–8.
98. Persson J, Johnsson E, Kostic S, et al. Treatment of achalasia with laparoscopic myotomy or pneumatic dilatation: Long-term results of a prospective, randomized study. *World J Surg* 2015;39(3):713–20.
99. Novais PA, Lemme EM. 24-h pH monitoring patterns and clinical response after achalasia treatment with pneumatic dilation or laparoscopic Heller myotomy. *Aliment Pharmacol Ther* 2010;32(10):1257–65.
100. Cheng JW, Li Y, Xing WQ, et al. Laparoscopic Heller myotomy is not superior to pneumatic dilation in the management of primary achalasia: Conclusions of a systematic review and meta-analysis of randomized controlled trials. *Medicine (Baltimore)* 2017;96(7):e5525.
101. Schoenberg MB, Marx S, Kersten JF, et al. Laparoscopic Heller myotomy versus endoscopic balloon dilatation for the treatment of achalasia: A network meta-analysis. *Ann Surg* 2013;258(6):943–52.
102. Yaghoobi M, Mayrand S, Martel M, et al. Laparoscopic Heller's myotomy versus pneumatic dilation in the treatment of idiopathic achalasia: A meta-analysis of randomized, controlled trials. *Gastrointest Endosc* 2013;78(3):468–75.
103. Harvey PR, Coupland B, Mytton J, et al. Outcomes of pneumatic dilation and Heller's myotomy for achalasia in England between 2005 and 2016. *Gut* 2019;68:1146–51.
104. Chrystoja CC, Darling GE, Diamant NE, et al. Achalasia-specific quality of life after pneumatic dilation or laparoscopic Heller myotomy with partial fundoplication: A multicenter, randomized clinical trial. *Am J Gastroenterol* 2016;111(11):1536–45.
105. Markar SR, Mackenzie H, Askari A, et al. Population-based cohort study of surgical myotomy and pneumatic dilatation as primary interventions for oesophageal achalasia. *Br J Surg* 2018;105(8):1028–35.
106. Boeckxstaens GE, Annese V, des Varannes SB, et al. Pneumatic dilation versus laparoscopic Heller's myotomy for idiopathic achalasia. *N Engl J Med* 2011;364(19):1807–16.
107. Gray RT, Coleman HG, Lau KW, et al. Heller's myotomy and pneumatic dilation in the treatment of achalasia: A population-based case-control study assessing long-term quality of life. *Dis Esophagus* 2017;30(3):1–7.
108. Sanaka MR, Hayat U, Thota PN, et al. Efficacy of peroral endoscopic myotomy vs other achalasia treatments in improving esophageal function. *World J Gastroenterol* 2016;22(20):4918–25.
109. Zaninotto G, Annese V, Costantini M, et al. Randomized controlled trial of botulinum toxin versus laparoscopic heller myotomy for esophageal achalasia. *Ann Surg* 2004;239(3):364–70.
110. Zaninotto G, Vergadoro V, Annese V, et al. Botulinum toxin injection versus laparoscopic myotomy for the treatment of esophageal achalasia: Economic analysis of a randomized trial. *Surg Endosc* 2004;18(4):691–5.
111. Werner YB, Hakanson B, Martinek J, et al. Endoscopic or surgical myotomy in patients with idiopathic achalasia. *N Engl J Med* 2019;381(23):2219–29.
112. Awaiz A, Yunus RM, Khan S, et al. Systematic review and meta-analysis of perioperative outcomes of peroral endoscopic myotomy (POEM) and laparoscopic Heller myotomy (LHM) for achalasia. *Surg Laparosc Endosc Percutan Tech* 2017;27(3):123–31.
113. Bhayani NH, Kurian AA, Dunst CM, et al. A comparative study on comprehensive, objective outcomes of laparoscopic Heller myotomy with per-oral endoscopic myotomy (POEM) for achalasia. *Ann Surg* 2014;259(6):1098–103.
114. Chan SM, Wu JC, Teoh AY, et al. Comparison of early outcomes and quality of life after laparoscopic Heller's cardiomyotomy to peroral endoscopic myotomy for treatment of achalasia. *Dig Endosc* 2016;28(1):27–32.
115. Schneider AM, Louie BE, Warren HF, et al. A matched comparison of per oral endoscopic myotomy to laparoscopic Heller myotomy in the treatment of achalasia. *J Gastrointest Surg* 2016;20(11):1789–96.
116. Teitelbaum EN, Rajeswaran S, Zhang R, et al. Peroral esophageal myotomy (POEM) and laparoscopic Heller myotomy produce a similar short-term anatomic and functional effect. *Surgery* 2013;154(4):885–91; discussion 91–2.
117. Vaezi MF, Baker ME, Achkar E, et al. Timed barium oesophagram: Better predictor of long term success after pneumatic dilation in achalasia than symptom assessment. *Gut* 2002;50(6):765–70.

118. Vaezi MF, Baker ME, Richter JE. Assessment of esophageal emptying post-pneumatic dilation: Use of the timed barium esophagram. *Am J Gastroenterol* 1999;94(7):1802-7.
119. Jain AS, Carlson DA, Triggs J, et al. Esophagogastric junction distensibility on functional lumen imaging probe topography predicts treatment response in achalasia-anatomy matters!. *Am J Gastroenterol* 2019;114:1455-63.
120. Patel DA, Sharda R, Hovis KL, et al. Patient-reported outcome measures in dysphagia: A systematic review of instrument development and validation. *Dis Esophagus* 2017;30(5):1-23.
121. Gockel I, Junginger T. The value of scoring achalasia: A comparison of current systems and the impact on treatment—The surgeon's viewpoint. *Am Surg* 2007;73(4):327-31.
122. Eckardt VF, Gockel I, Bernhard G. Pneumatic dilation for achalasia: Late results of a prospective follow up investigation. *Gut* 2004;53(5):629-33.
123. Taft TH, Carlson DA, Triggs J, et al. Evaluating the reliability and construct validity of the Eckardt symptom score as a measure of achalasia severity. *Neurogastroenterol Motil* 2018;30(6):e13287.
124. Rohof WO, Lei A, Boeckxstaens GE. Esophageal stasis on a timed barium esophagogram predicts recurrent symptoms in patients with long-standing achalasia. *Am J Gastroenterol* 2013;108(1):49-55.
125. Blonski W, Kumar A, Feldman J, et al. Timed barium swallow: Diagnostic role and predictive value in untreated achalasia, esophagogastric junction outflow obstruction, and non-achalasia dysphagia. *Am J Gastroenterol* 2018;113(2):196-203.
126. Nicodeme F, de Ruigh A, Xiao Y, et al. A comparison of symptom severity and bolus retention with Chicago classification esophageal pressure topography metrics in patients with achalasia. *Clin Gastroenterol Hepatol* 2013;11(2):131-7. quiz e15.
127. van Hoeij FB, Smout A, Bredenoord AJ. Esophageal stasis in achalasia patients without symptoms after treatment does not predict symptom recurrence. *Neurogastroenterol Motil* 2017;29(8):e13059.
128. Krieger-Grubel C, Tutuiari R, Borovicka J. Correlation of esophageal clearance and dysphagia symptom assessment after treatment for achalasia. *United Eur Gastroenterol J* 2016;4(1):55-61.
129. Guardino JM, Vela MF, Connor JT, et al. Pneumatic dilation for the treatment of achalasia in untreated patients and patients with failed Heller myotomy. *J Clin Gastroenterol* 2004;38(10):855-60.
130. Kumbhari V, Behary J, Szczesniak M, et al. Efficacy and safety of pneumatic dilatation for achalasia in the treatment of post-myotomy symptom relapse. *Am J Gastroenterol* 2013;108(7):1076-81.
131. Legros L, Ropert A, Brochard C, et al. Long-term results of pneumatic dilatation for relapsing symptoms of achalasia after Heller myotomy. *Neurogastroenterol Motil* 2014;26(9):1248-55.
132. Saleh CM, Ponds FA, Schijven MP, et al. Efficacy of pneumodilation in achalasia after failed Heller myotomy. *Neurogastroenterol Motil* 2016;28(11):1741-6.
133. Amani M, Fazlollahi N, Shirani S, et al. Assessment of pneumatic balloon dilation in patients with symptomatic relapse after failed Heller myotomy: A single center experience. *Middle East J Dig Dis* 2016;8(1):57-62.
134. Fernandez-Ananin S, Fernandez AF, Balague C, et al. What to do when Heller's myotomy fails? Pneumatic dilatation, laparoscopic remyotomy or peroral endoscopic myotomy: A systematic review. *J Minim Access Surg* 2018;14(3):177-84.
135. van Hoeij FB, Ponds FA, Werner Y, et al. Management of recurrent symptoms after per-oral endoscopic myotomy in achalasia. *Gastrointest Endosc* 2018;87(1):95-101.
136. Werner YB, Costamagna G, Swanstrom LL, et al. Clinical response to peroral endoscopic myotomy in patients with idiopathic achalasia at a minimum follow-up of 2 years. *Gut* 2016;65(6):899-906.
137. Molena D, Mungo B, Stem M, et al. Outcomes of esophagectomy for esophageal achalasia in the United States. *J Gastrointest Surg* 2014;18(2):310-7.
138. Rosemurgy A, Downs D, Luberic K, et al. Laparoscopic Heller myotomy with anterior fundoplication improves frequency and severity of symptoms of achalasia, regardless of preoperative severity determined by esophagography. *Am Surg* 2018;84(2):165-73.
139. Giuliani L, Dubecz A, Stein HJ. [Laparoscopic Heller myotomy after failed POEM and multiple balloon dilatations: Better late than never]. *Chirurg* 2017;88(4):303-6. German.
140. Panchanatheeswaran K, Parshad R, Rohila J, et al. Laparoscopic Heller's cardiomyotomy: A viable treatment option for sigmoid oesophagus. *Interact Cardiovasc Thorac Surg* 2013;16(1):49-54.
141. Tyberg A, Sharaiha RZ, Familiari P, et al. Peroral endoscopic myotomy as salvation technique post-Heller: International experience. *Dig Endosc* 2018;30(1):52-6.
142. Ngamruengphong S, Inoue H, Ujiki MB, et al. Efficacy and safety of peroral endoscopic myotomy for treatment of achalasia after failed Heller myotomy. *Clin Gastroenterol Hepatol* 2017;15(10):1531-7 e3.
143. Zhang X, Modayil RJ, Friedel D, et al. Per-oral endoscopic myotomy in patients with or without prior Heller's myotomy: Comparing long-term outcomes in a large U.S. single-center cohort (with videos). *Gastrointest Endosc* 2018;87(4):972-85.
144. Ling T, Guo H, Zou X. Effect of peroral endoscopic myotomy in achalasia patients with failure of prior pneumatic dilation: A prospective case-control study. *J Gastroenterol Hepatol* 2014;29(8):1609-13.
145. Tang X, Gong W, Deng Z, et al. Feasibility and safety of peroral endoscopic myotomy for achalasia after failed endoscopic interventions. *Dis Esophagus* 2017;30(3):1-6.
146. Leeuwenburgh I, Scholten P, Alderliesten J, et al. Long-term esophageal cancer risk in patients with primary achalasia: A prospective study. *Am J Gastroenterol* 2010;105(10):2144-9.
147. Markar SR, Wiggins T, MacKenzie H, et al. Incidence and risk factors for esophageal cancer following achalasia treatment: National population-based case-control study. *Dis Esophagus* 2019;32(5):1-7.
148. Tustumi F, Bernardo WM, da Rocha JRM, et al. Esophageal achalasia: A risk factor for carcinoma. A systematic review and meta-analysis. *Dis Esophagus* 2017;30(10):1-8.
149. Sandler RS, Nyren O, Ekobom A, et al. The risk of esophageal cancer in patients with achalasia. A population-based study. *JAMA* 1995;274(17):1359-62.
150. ASGE Standards of Practice Committee; Evans JA, Early DS, Fukami N, et al. The role of endoscopy in Barrett's esophagus and other premalignant conditions of the esophagus. *Gastrointest Endosc* 2012;76(6):1087-94.
151. Eckardt AJ, Eckardt VF. Editorial: Cancer surveillance in achalasia: Better late than never? *Am J Gastroenterol* 2010;105(10):2150-2.