Dysphagia

Introduction

Inability to swallow is caused by a problem with the strength or coordination of the muscles required to move material from the mouth to the stomach or by a fixed obstruction somewhere between the mouth and stomach

Occasionally patients may have a combination of the two processes

Swallowing

complex neuromuscular activities

involving over 30 muscles

food passage from the oral cavity into stomach and protecting material from entering the airway.

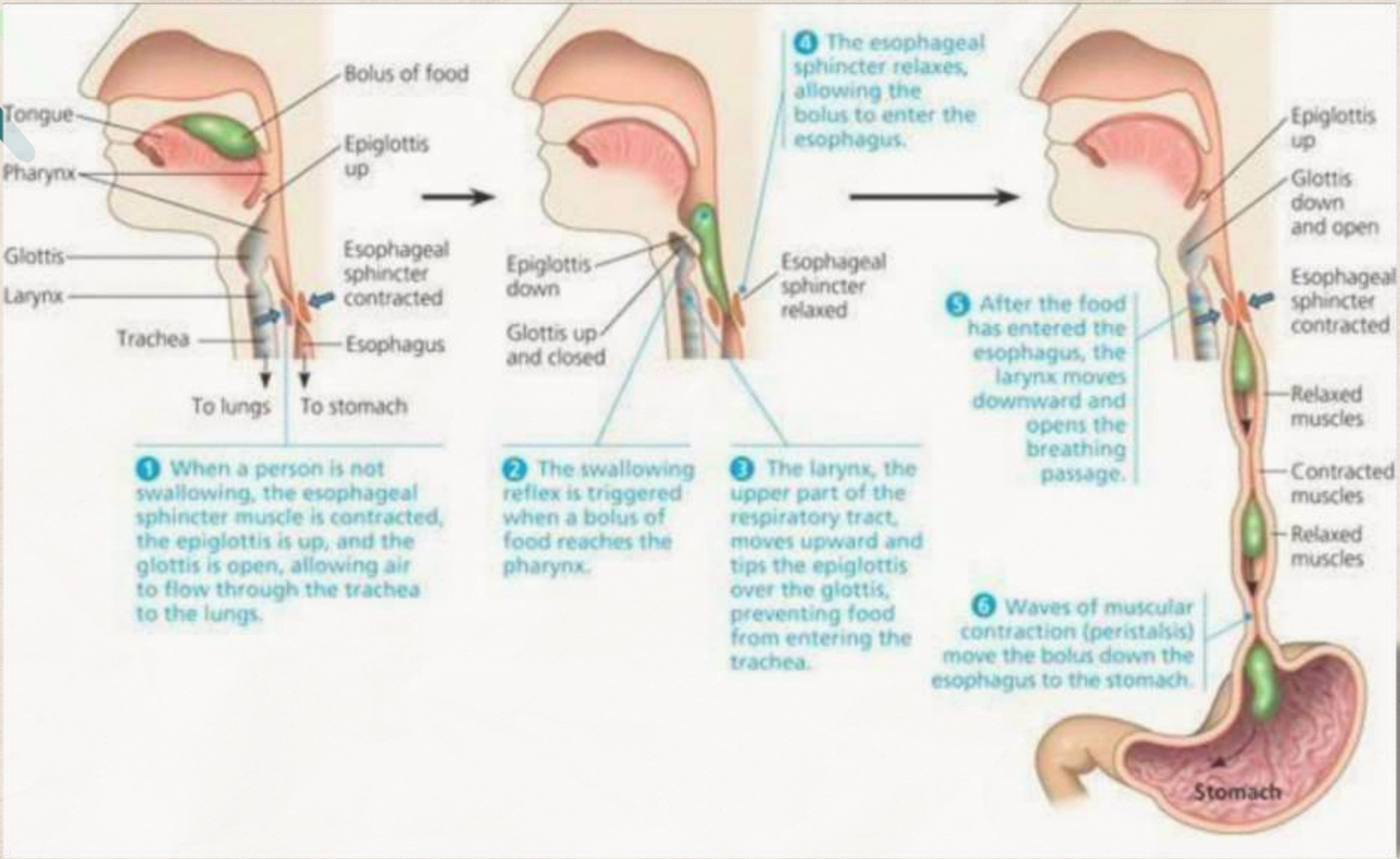

Bolus of food
Tongue
Pharynx
Epiglottis up
Glottis
Larynx
Esophageal sphincter contracted
Trachea
Esophagus
To lungs
To stomach
Epiglottis down
Glottis up and closed
Esophageal sphincter relaxed
Epiglottis up
Glottis down and open
Esophageal sphincter contracted
Relaxed muscles
Contracted muscles
Relaxed muscles
Stomach

① When a person is not swallowing, the esophageal sphincter muscle is contracted, the epiglottis is up, and the glottis is open, allowing air to flow through the trachea to the lungs.

② The swallowing reflex is triggered when a bolus of food reaches the pharynx.

③ The larynx, the upper part of the respiratory tract, moves upward and tips the epiglottis over the glottis, preventing food from entering the trachea.

④ The esophageal sphincter relaxes, allowing the bolus to enter the esophagus.

⑤ After the food has entered the esophagus, the larynx moves downward and opens the breathing passage.

⑥ Waves of muscular contraction (peristalsis) move the bolus down the esophagus to the stomach.

oral

Pharyngeal

Esophageal

Oral Phase

1

the oral preparatory stage:

chewed
mixed with saliva

2

the oral stage:

voluntary phase
tongue

Pharyngeal Phase

.occurring within a second
begins with the initiation of a voluntary
through the pharynx and UES to the esophagus
bolus triggers the involuntary swallowing reflex.
airway protection

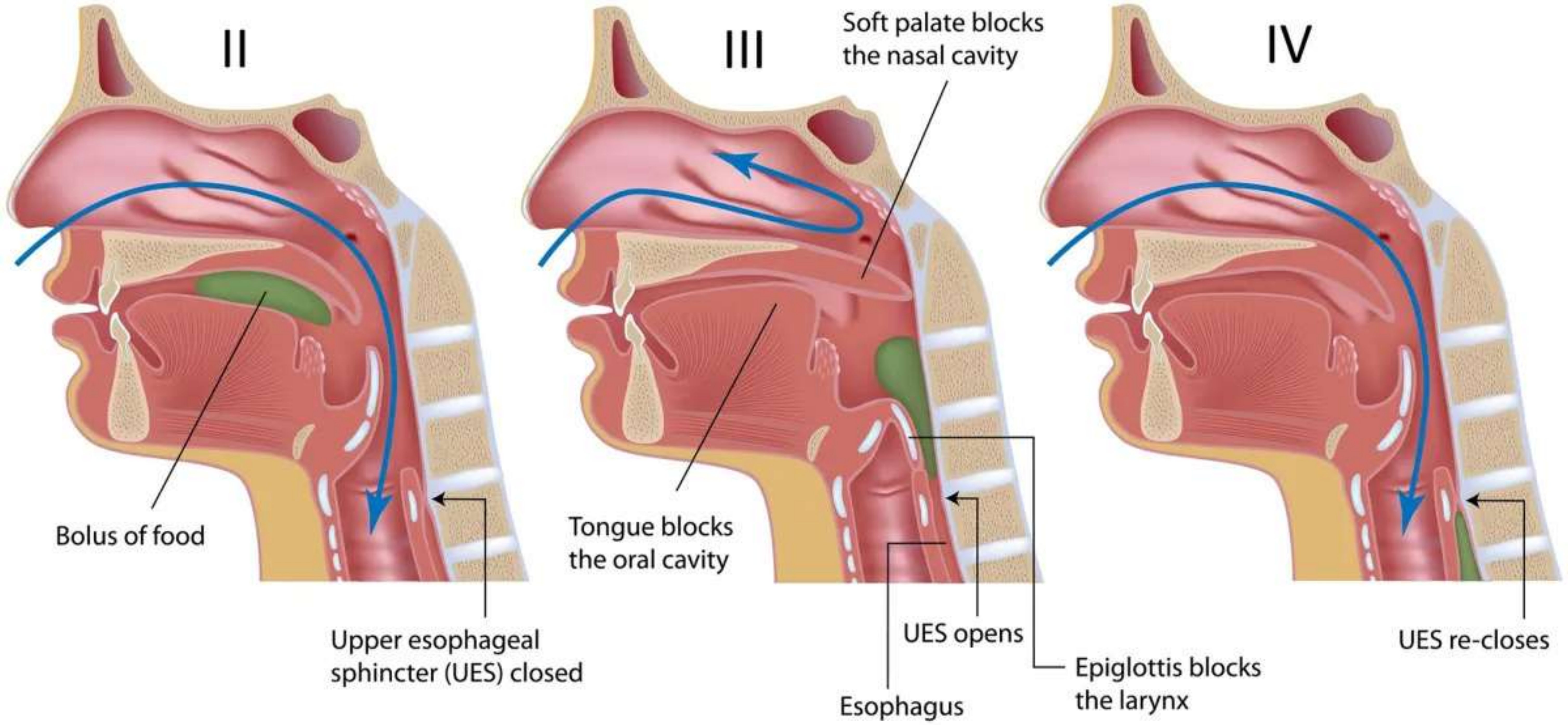
II
III
Soft palate blocks the nasal cavity
IV
Bolus of food
Tongue blocks the oral cavity
Upper esophageal sphincter (UES) closed
UES opens
UES re-closes
Epiglottis blocks the larynx
Esophagus

Oropharyngeal Dysphagia

difficulty initiating a swallow
coughing or “choking
liquids are frequently more difficult than solids
patient often localizes the sensation

Causes

1

Neuromuscular

2

Mechanical obstruction

3

anatomical abnormalities

OROPHARYNGEAL DYSPHAGIA: CAUSES & TREATMENTS

Summarized from Table 3.1, Mayo Clinic

NEUROMUSCULAR & NEUROLOGICAL DISORDERS

CAUSES

- Stroke (Cerebrovascular Accident)
- Amyotrophic Lateral Sclerosis (ALS)
- Parkinson's disease
- Multiple Sclerosis (MS)

TREATMENT: SWALLOWING REHABILITATION & MEDICAL CARE

- Swallowing exercises & specialized therapy
- Medical management of underlying disorders (e.g., medication for Parkinson's)

MECHANICAL OBSTRUCTION

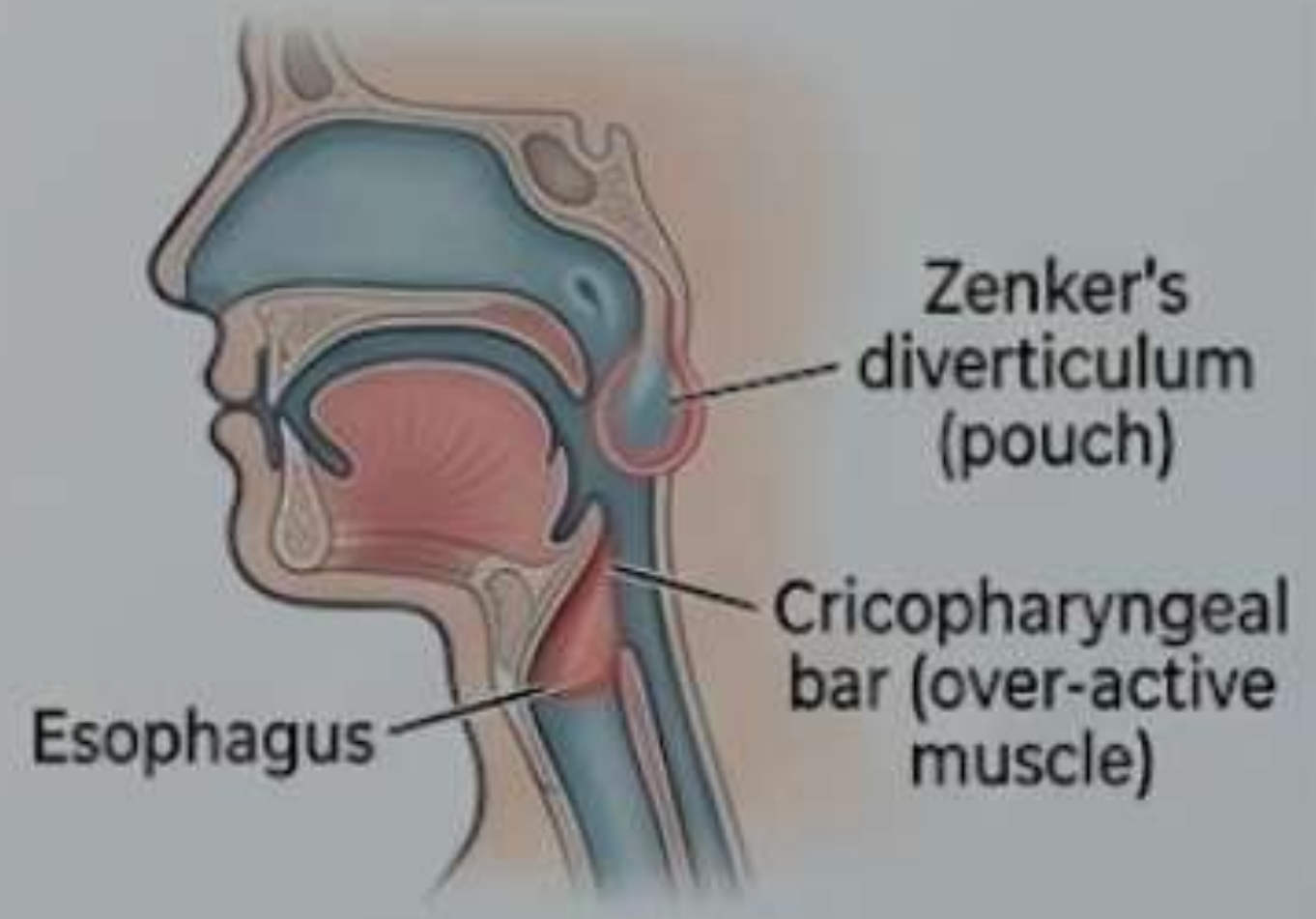
Zenker's diverticulum (pouch)
Cricopharyngeal bar (over-active muscle)
Esophagus

CAUSES

- Zenker diverticulum
- Cricopharyngeal bar

TREATMENT: SPECIALIZED PROCEDURES

- Bougie dilatation
- Botulinum Toxin injection
- Cricopharyngeal Myotomy (simplified surgery icon)

STRUCTURAL ISSUES

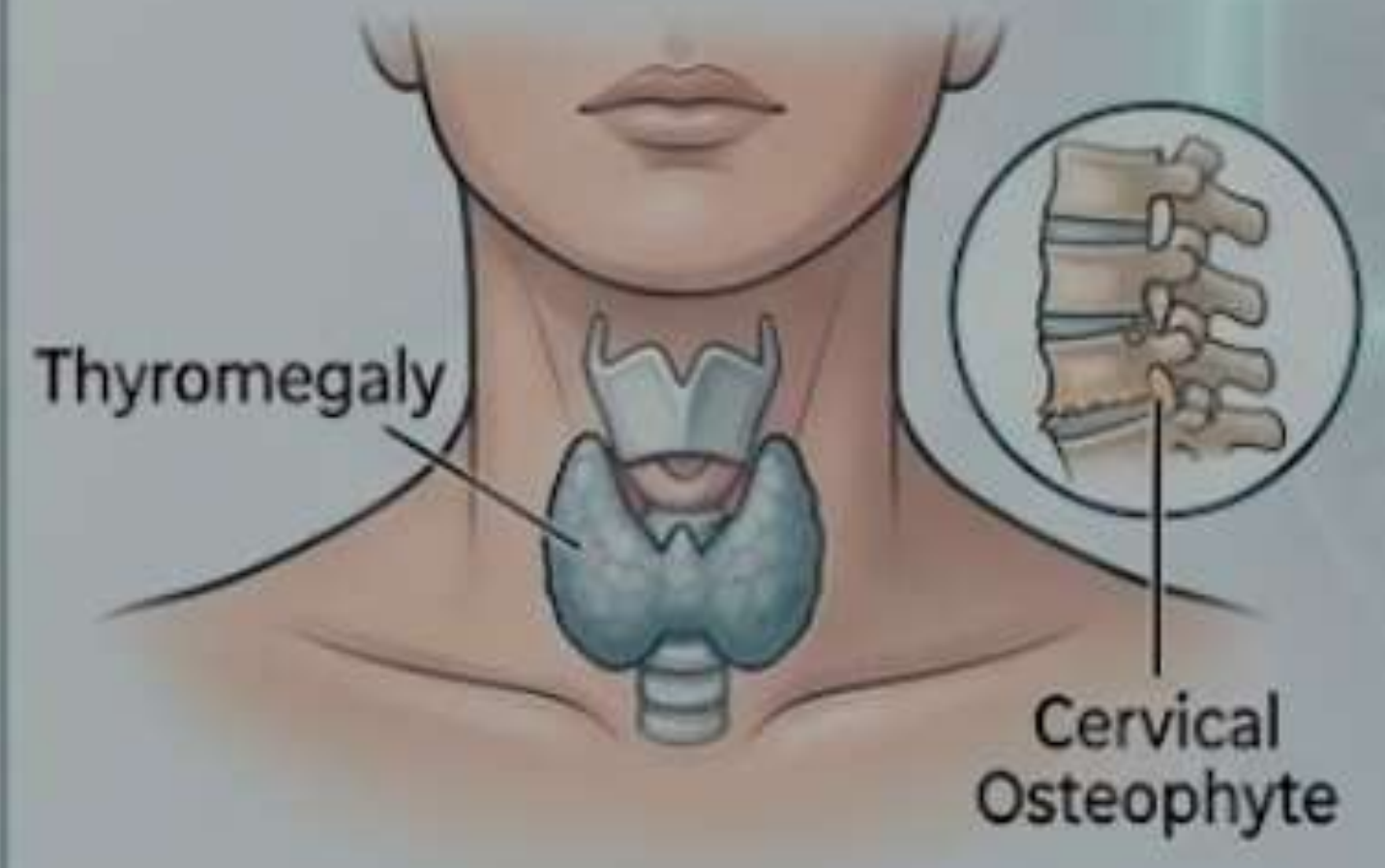
Thyromegaly
Cervical Osteophyte

CAUSES

- Thyromegaly
- Cervical osteophyte

TREATMENT: MEDICAL & SURGICAL OPTIONS

- Medical treatment (for underlying conditions)
- Surgery (for severe cases)

Esophageal Phase

from the lower part of the UES to the lower esophageal sphincter (LES)

tensioned at rest to prevent regurgitation from the stomach.

It relaxes during a swallow

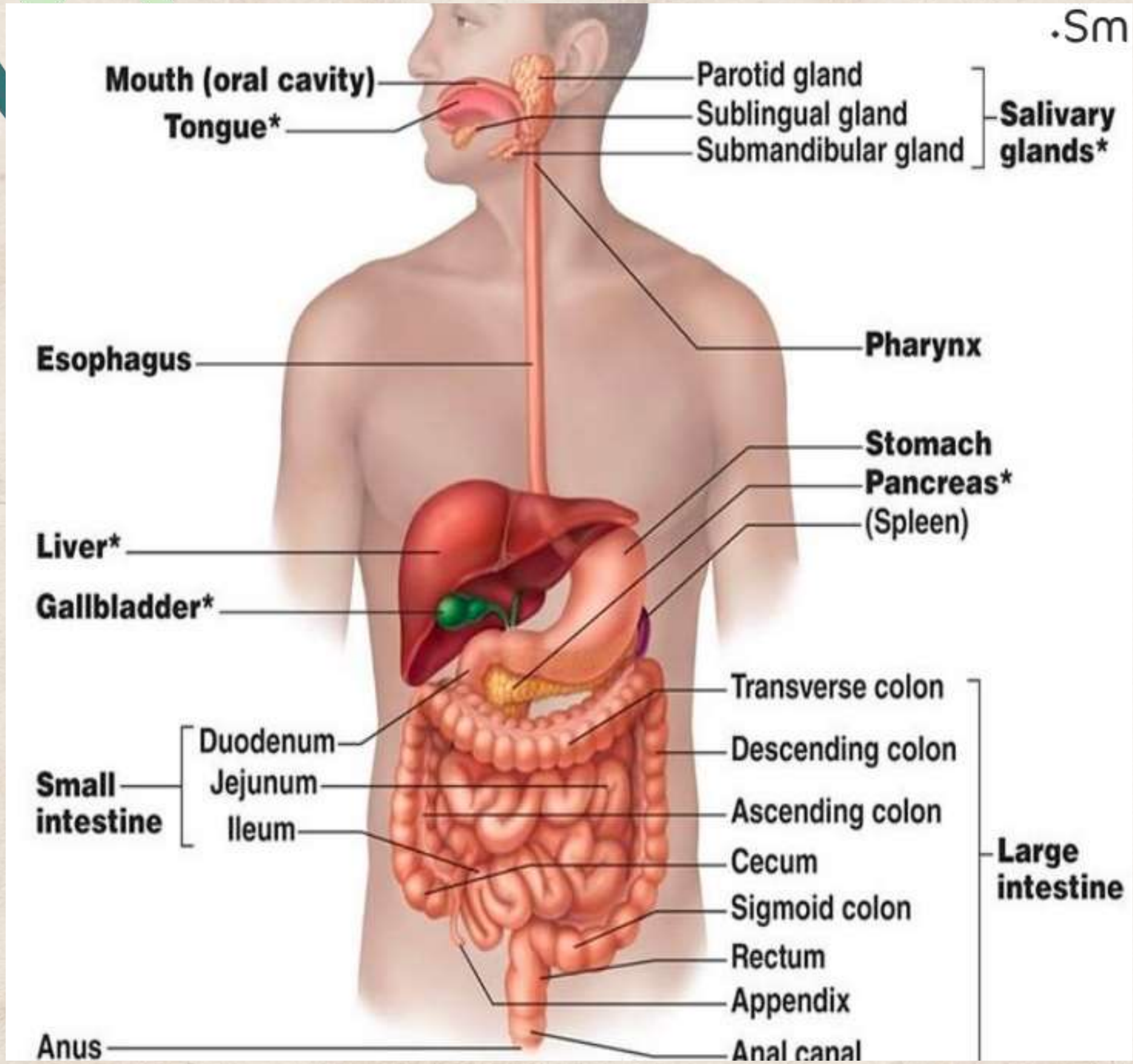
.Sm
Mouth (oral cavity)
Tongue*
Parotid gland
Sublingual gland
Submandibular gland
Salivary glands*
Esophagus
Pharynx
Stomach
Pancreas*
(Spleen)
Liver*
Gallbladder*
Transverse colon
Descending colon
Ascending colon
Cecum
Sigmoid colon
Rectum
Appendix
Anal canal
Large intestine
Small intestine
Duodenum
Jejunum
Ileum
Anus

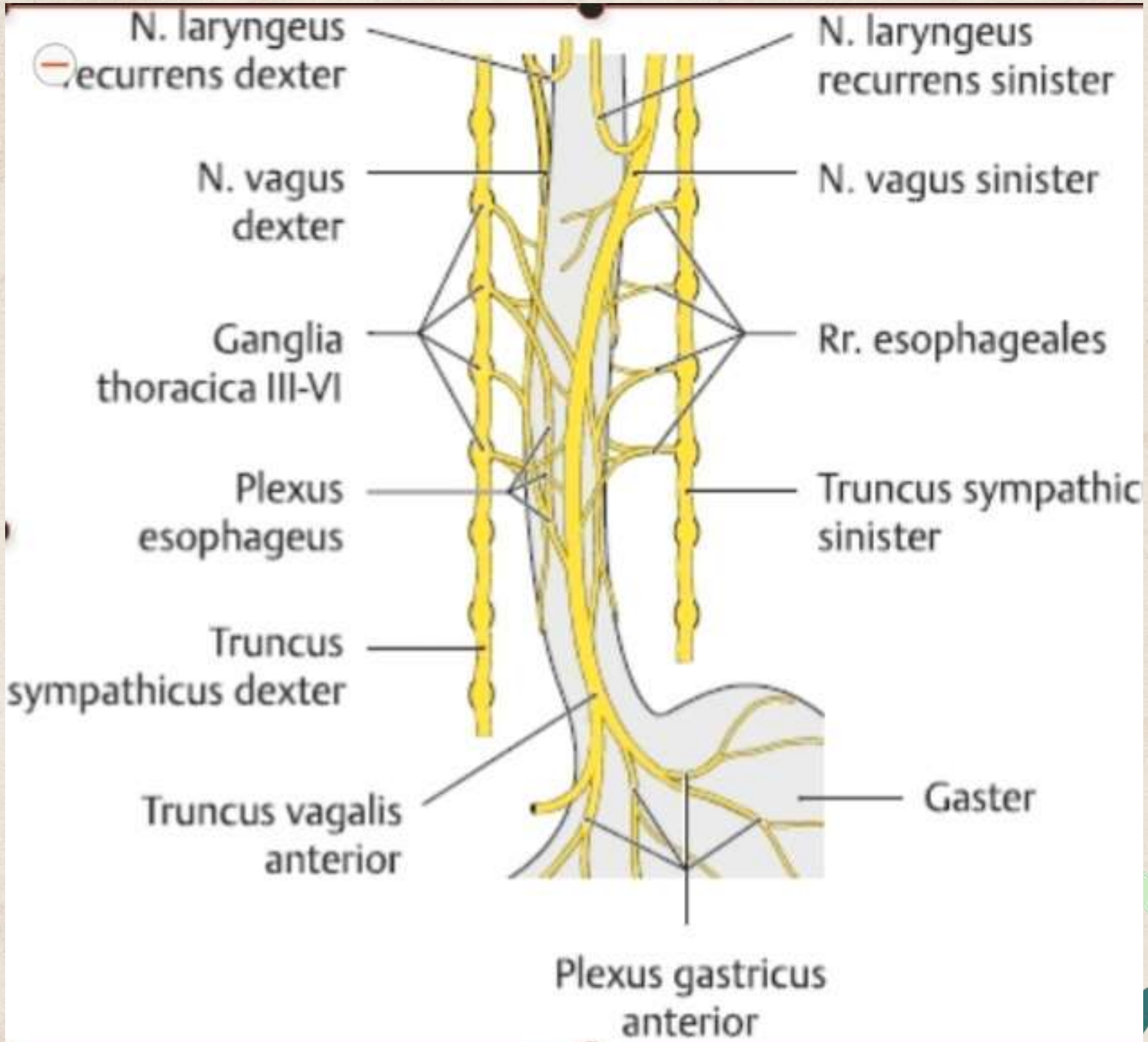
N. laryngeus
ecurrens dexter
N. laryngeus recurrens sinister
N. vagus dexter
N. vagus sinister
Ganglia thoracica III-VI
Rr. esophageales
Plexus esophageus
Truncus sympathic sinister
Truncus sympathicus dexter
Truncus vagalis anterior
Gaster
Plexus gastricus anterior

What type of food or liquid causes symptoms?

Is the dysphagia intermittent or progressive ?

Does the patient have heartburn?

STRUCTURAL (MECHANICAL) DISORDERS

Intrinsic

- Carcinoma and benign tumors
- Diverticula
- Eosinophilic esophagitis
- Esophageal rings and webs (other than Schatzki ring)
- Foreign body
- Lower esophageal (Schatzki ring
- Medication-induced stricture
- Peptic stricture

Extrinsic

- Mediastinal mass
- Spinal osteophytes
- Vascular compression

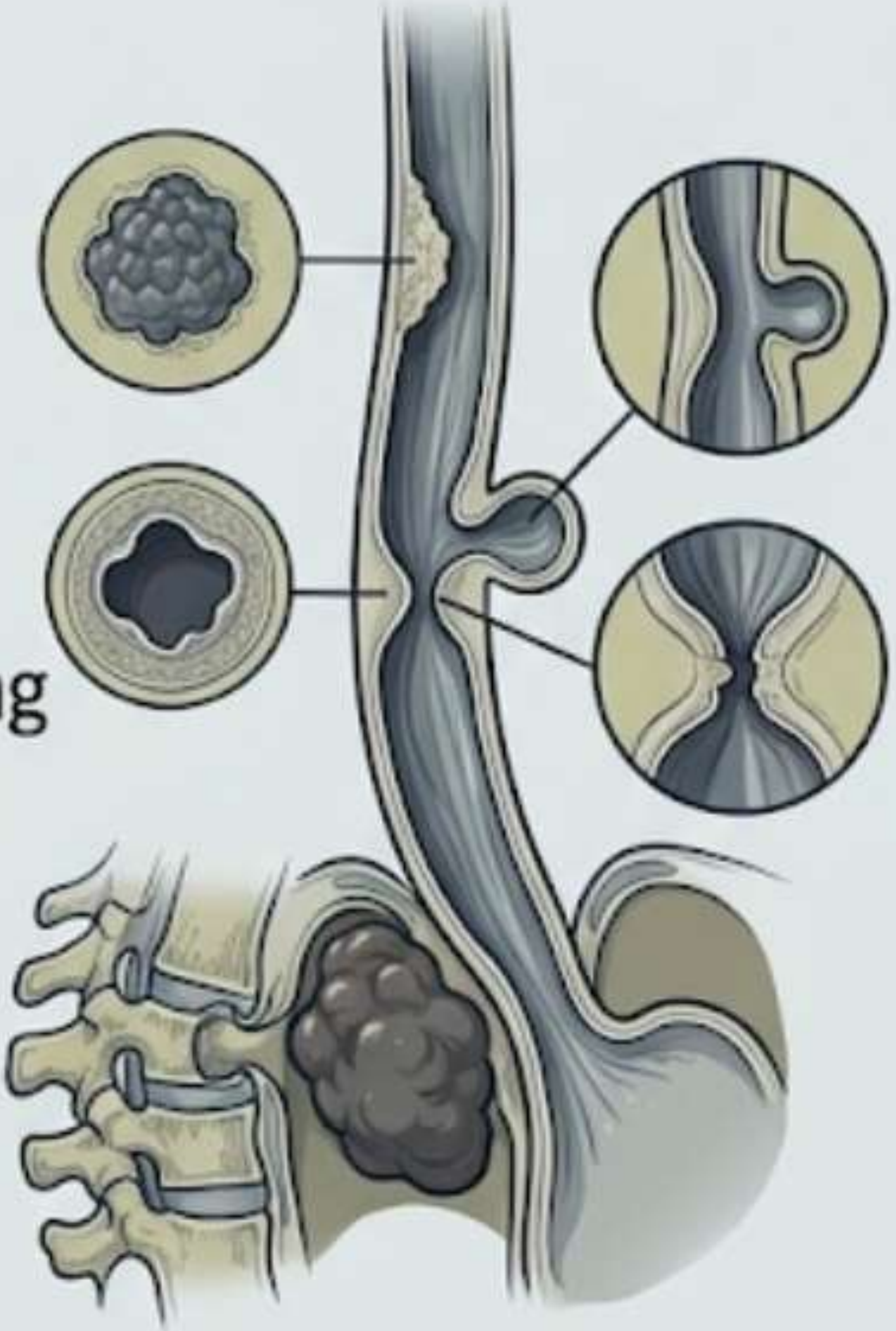

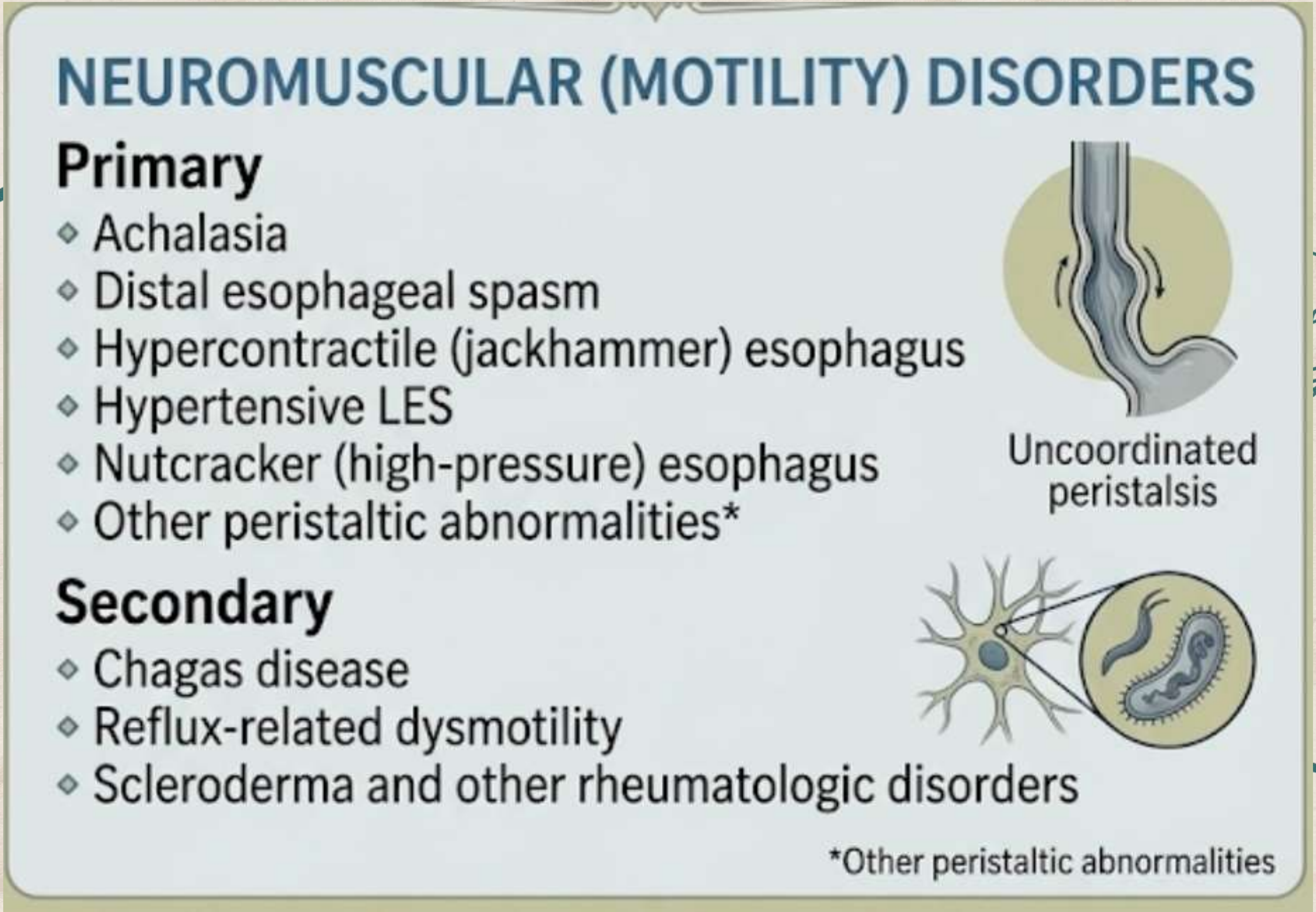

NEUROMUSCULAR (MOTILITY) DISORDERS

Primary

- Achalasia
- Distal esophageal spasm
- Hypercontractile (jackhammer) esophagus
- Hypertensive LES
- Nutcracker (high-pressure) esophagus
- Other peristaltic abnormalities*

Uncoordinated peristalsis

Secondary

- Chagas disease
- Reflux-related dysmotility
- Scleroderma and other rheumatologic disorders

*Other peristaltic abnormalities

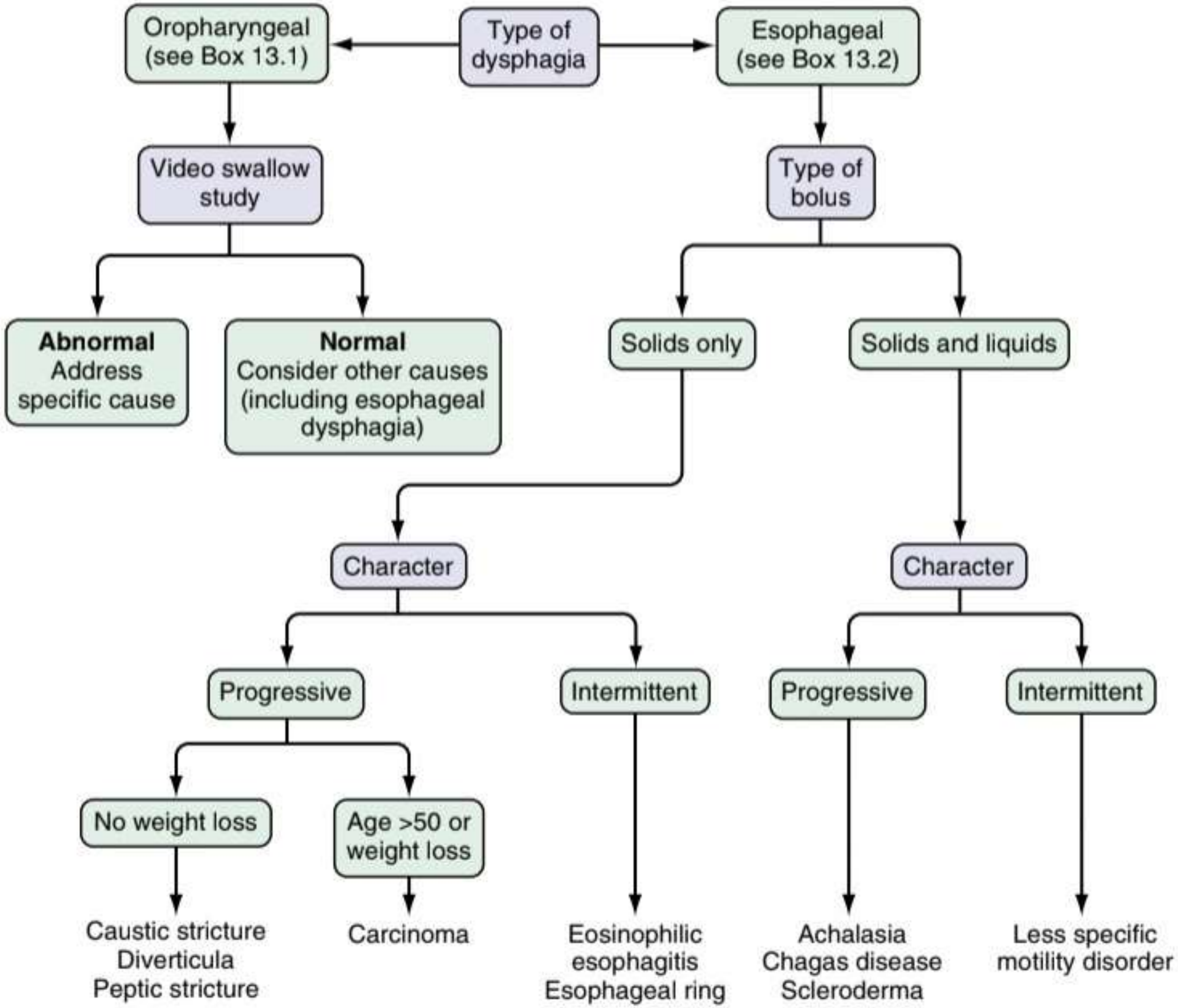

Type of dysphagia

Oropharyngeal (see Box 13.1)

Video swallow study

Abnormal Address specific cause

Normal Consider other causes (including esophageal dysphagia)

Esophageal (see Box 13.2)

Type of bolus

Solids only

Character

Progressive

No weight loss

Caustic stricture
Diverticula
Peptic stricture

Age >50 or weight loss

Carcinoma

Intermittent

Eosinophilic esophagitis
Esophageal ring

Solids and liquids

Character

Progressive

Achalasia
Chagas disease
Scleroderma

Intermittent

Less specific motility disorder

Diagnosis

1

Endoscopy

2

Barium esophagram

3

esophageal manometry

Endoscopy

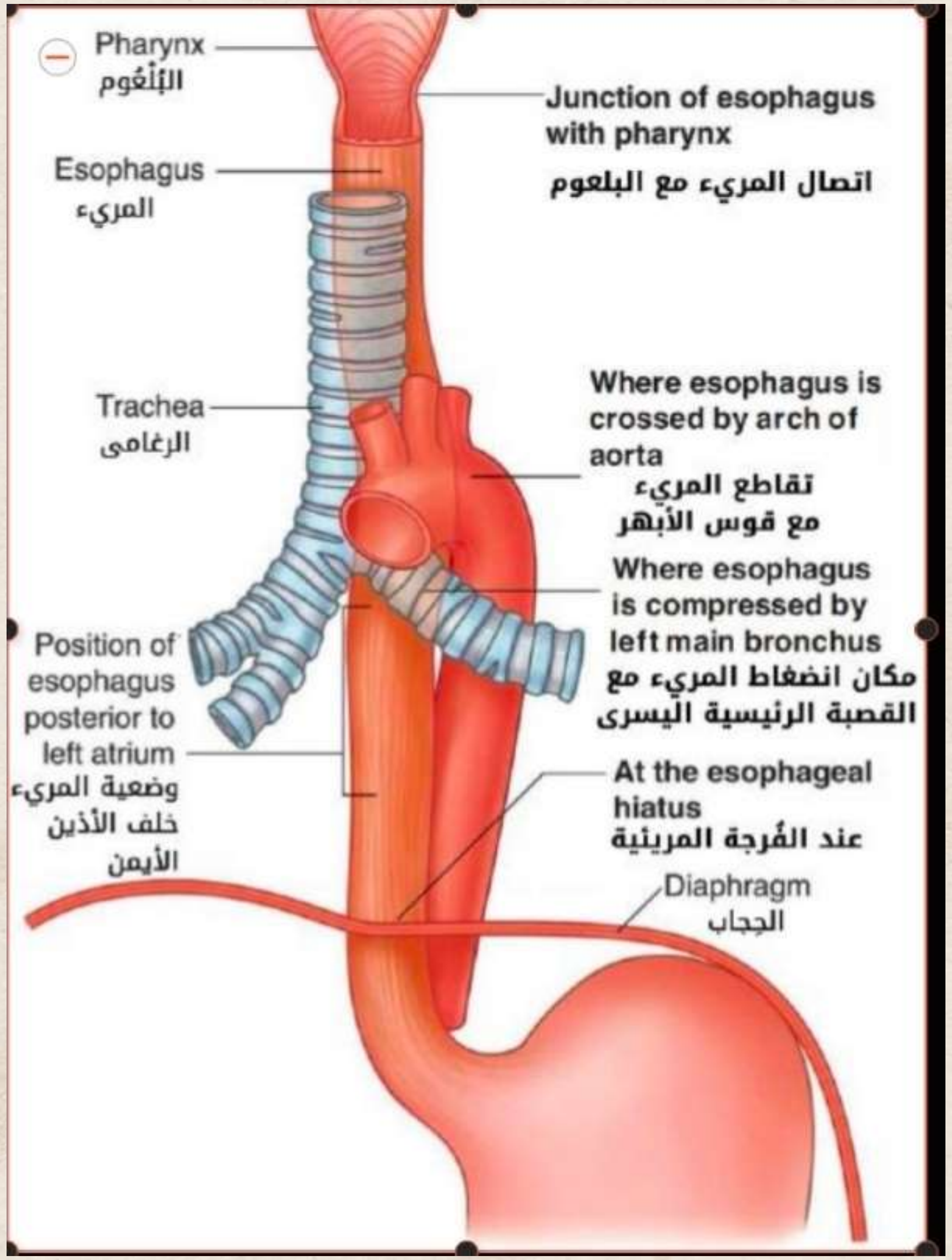
Pharynx
البُلْعُوم
Esophagus
المريء
Trachea
الرغامى
Position of esophagus posterior to left atrium
وضعية المريء خلف الأذين الأيمن
Junction of esophagus with pharynx
اتصال المريء مع البلعوم
Where esophagus is crossed by arch of aorta
تقاطع المريء مع قوس الأبهر
Where esophagus is compressed by left main bronchus
مكان انضغاط المريء مع القصبة الرئيسية اليسرى
At the esophageal hiatus
عند الفُرجة المريئية
Diaphragm
الحجاب

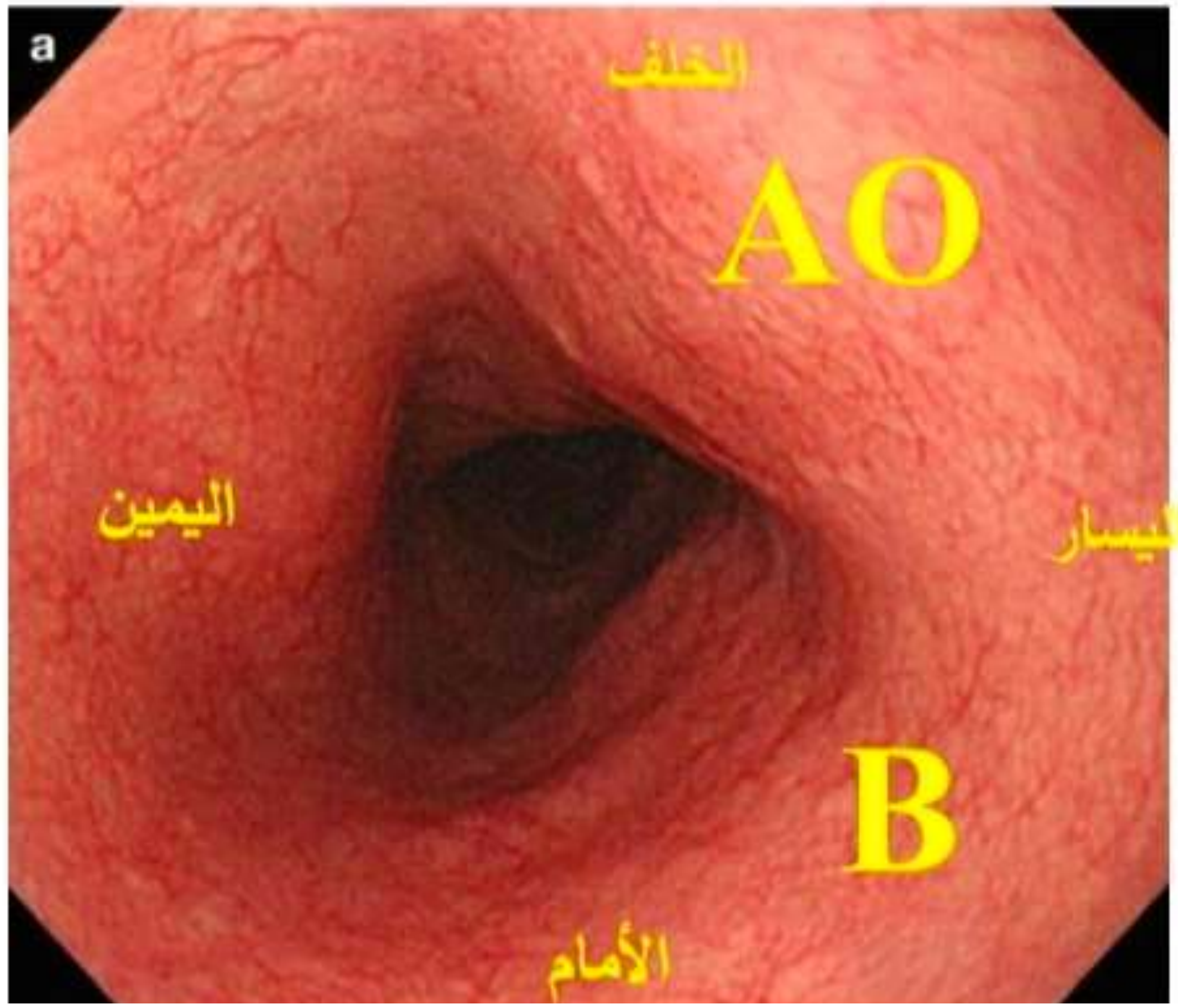
a
الخلف
AO
اليمين
اليسار
B
الأمام

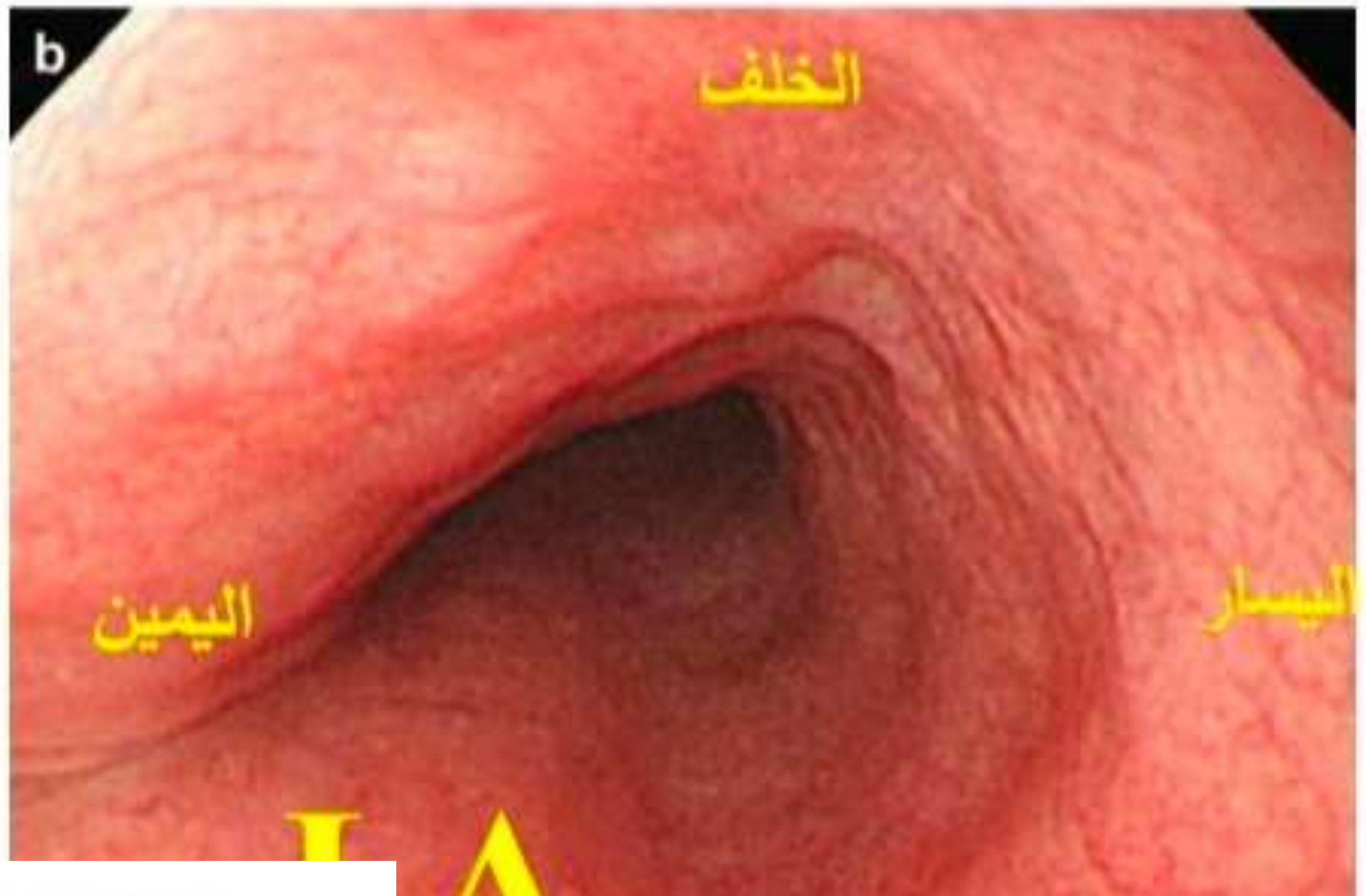
b
الخلف
اليمين
اليسار
LA
الأمام

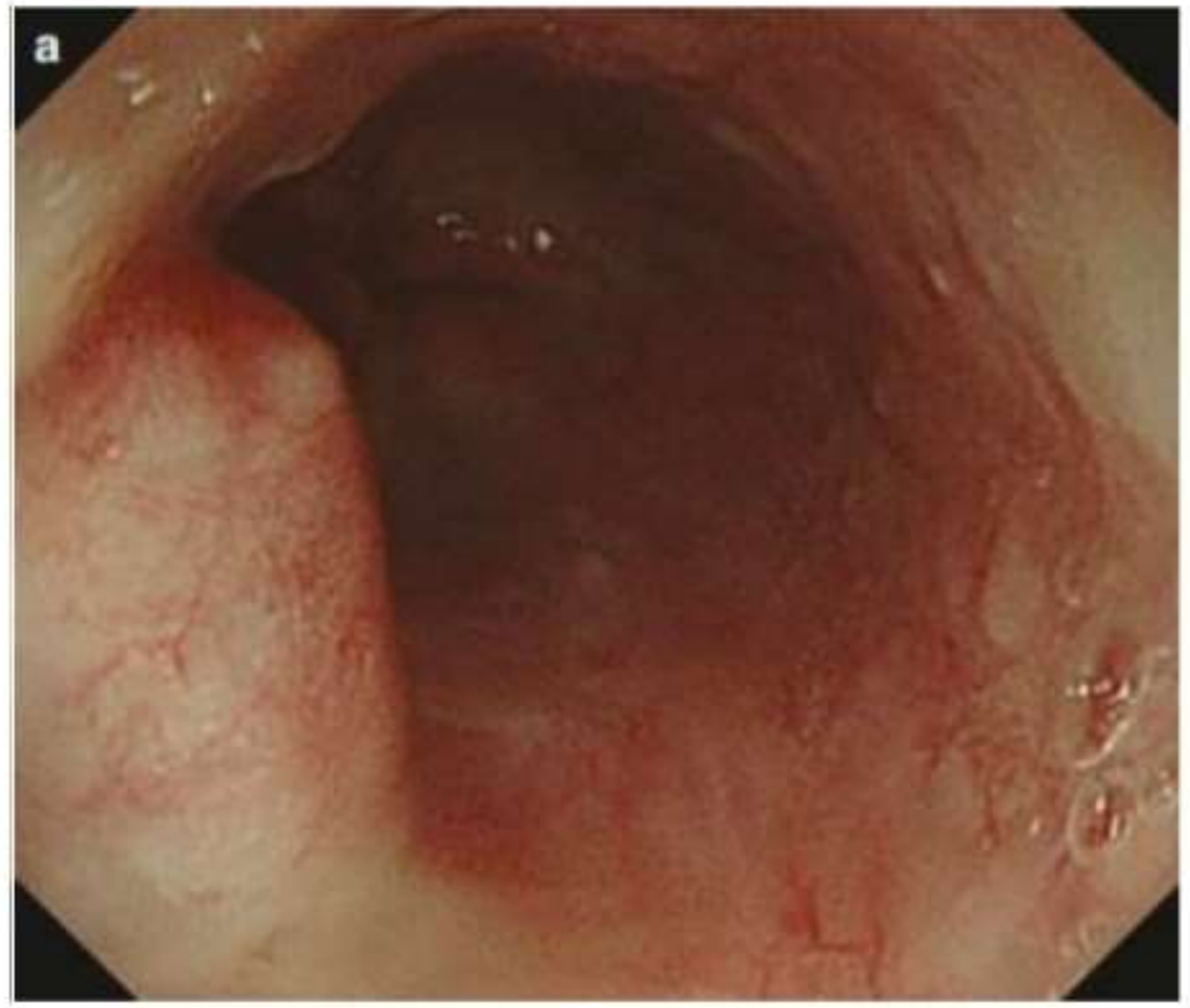

تبارز مغطى بمخاطية سليمة في الجزء القاصي من المري

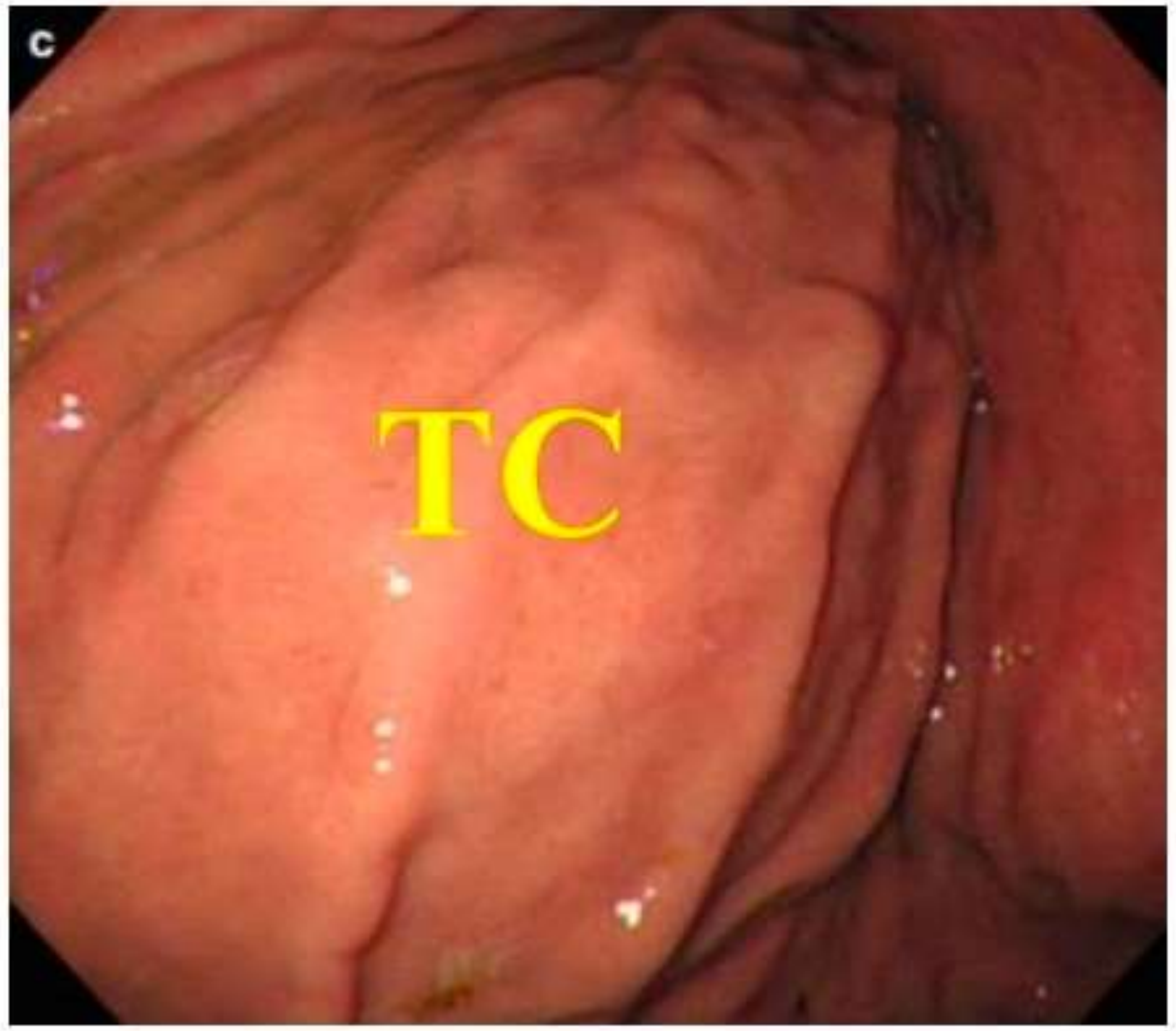

انضغاط خارجي للانحناء الكبير بالكولون المستعرض TC

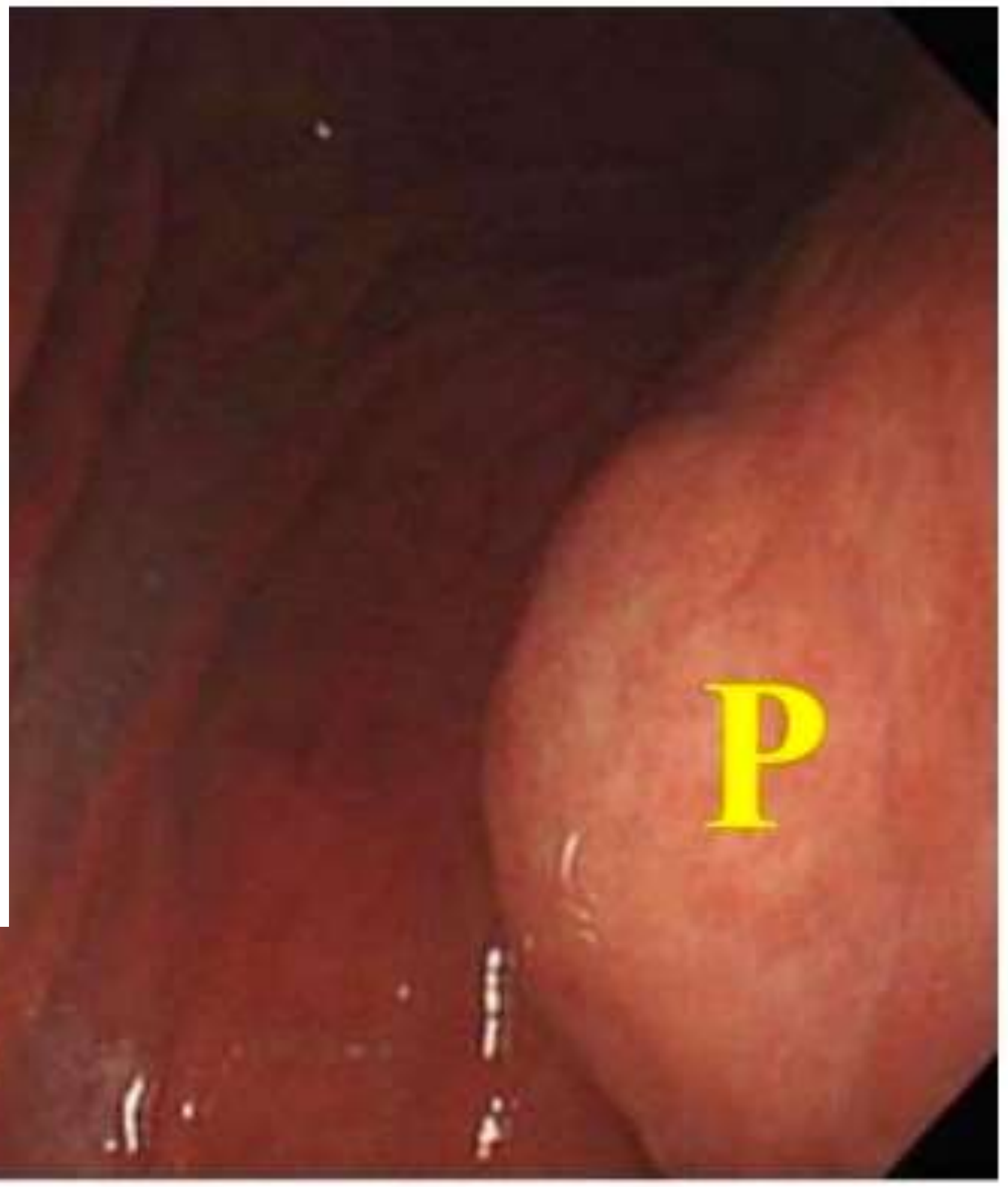

انضغاط خارجي للوجه الخلفي للمعدة بالبنكرياس P

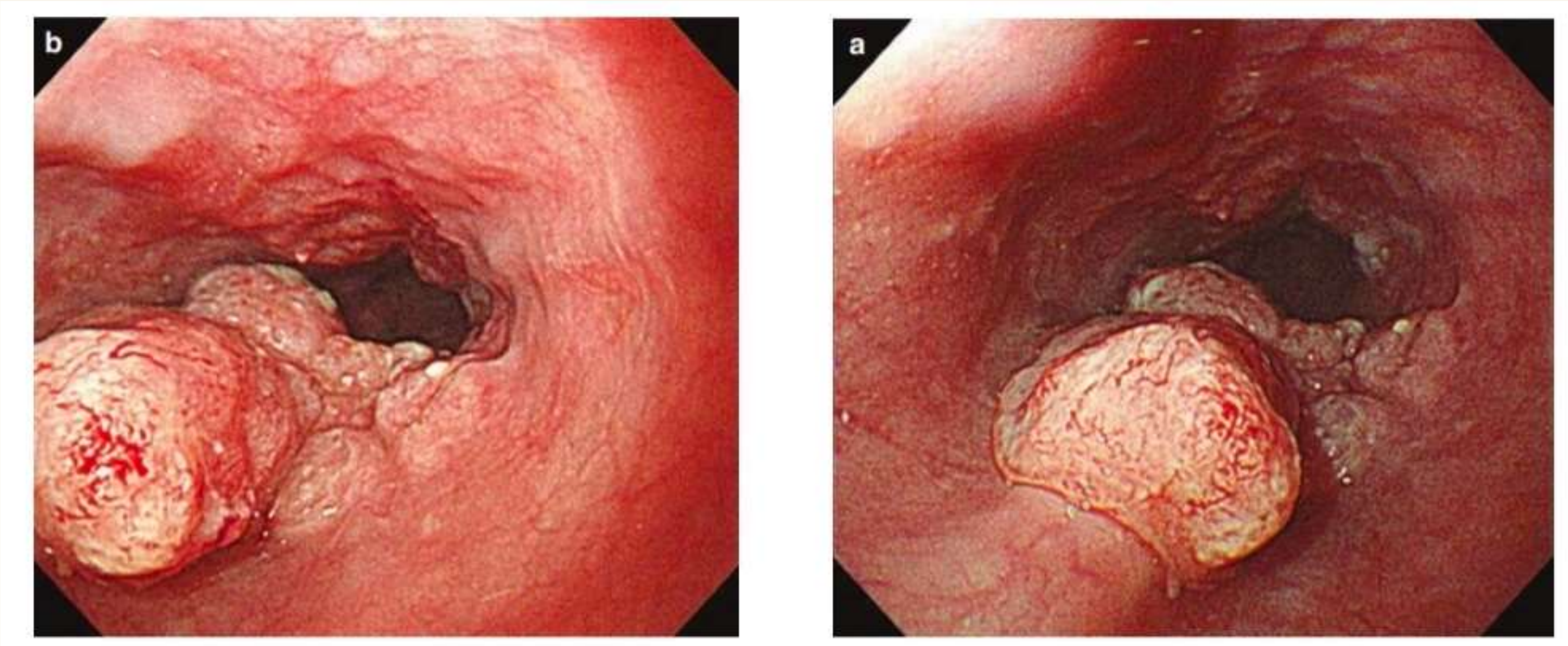
b
a

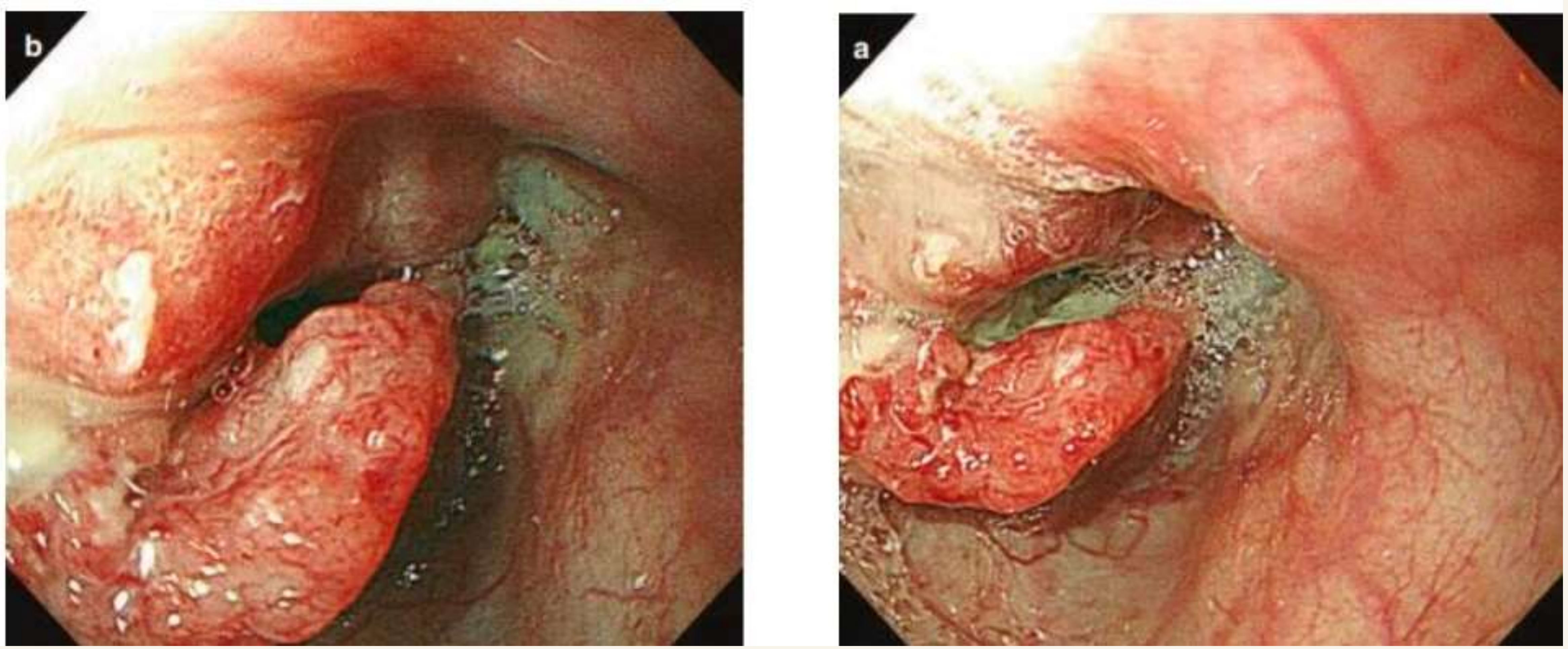
b
a

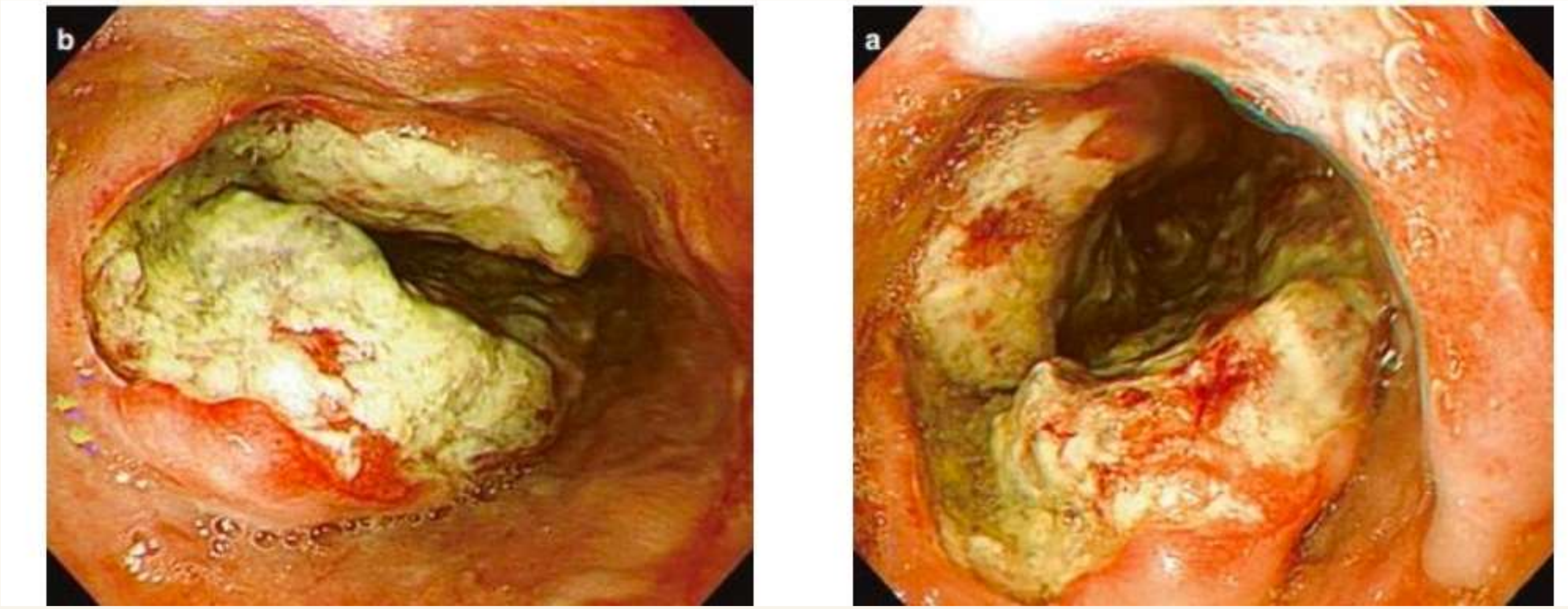

Esophageal Cancer

Esophageal Cancer – TNM Staging (AJCC 8th Edition)

T – Primary Tumor

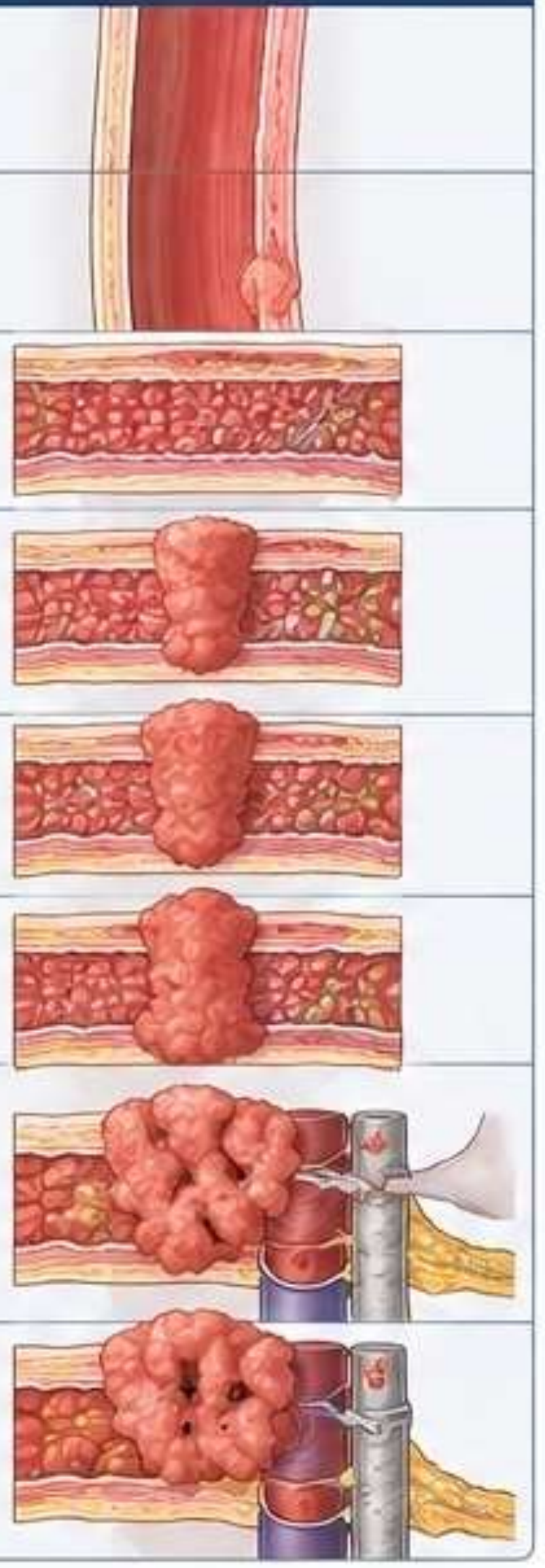

TX	Primary tumor cannot be assessed
T0	No evidence of primary tumor
Tis	Carcinoma in situ (high-grade dysplasia)
T1	Tumor invades lamina propria, muscularis mucosae, or submucosa
T2	Tumor invades muscularis propria
T3	Tumor invades adventitia
T4a	Tumor invades resectable adjacent structures (pleura, pericardium, azygos vein, diaphragm)
T4b	Tumor invades unresectable adjacent structures (aorta, vertebral body, trachea)

N – Regional Lymph Nodes

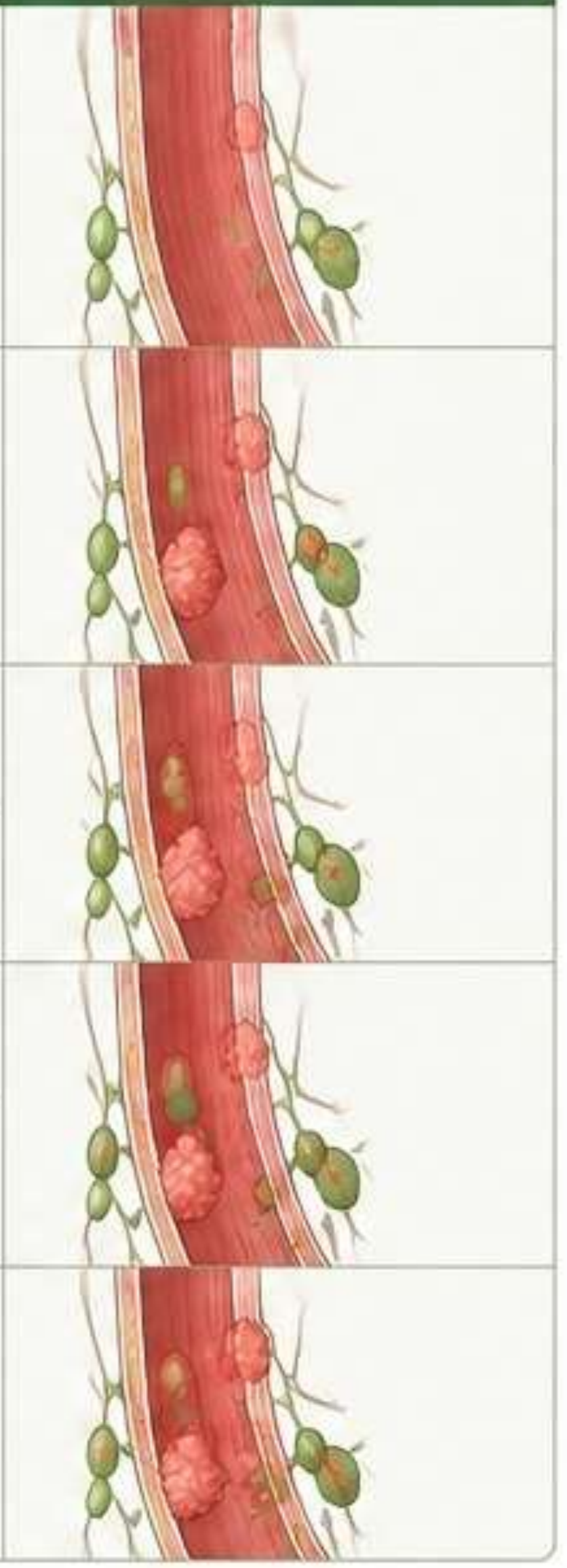

NX	Regional lymph nodes cannot be assessed
N0	No regional lymph node metastasis
N1	Metastasis in 1–2 regional lymph nodes
N2	Metastasis in 3–6 regional lymph nodes
N3	Metastasis in 7 or more regional lymph nodes

M – Distant Metastasis

M0	No distant metastasis
M1	Distant metastasis (present)

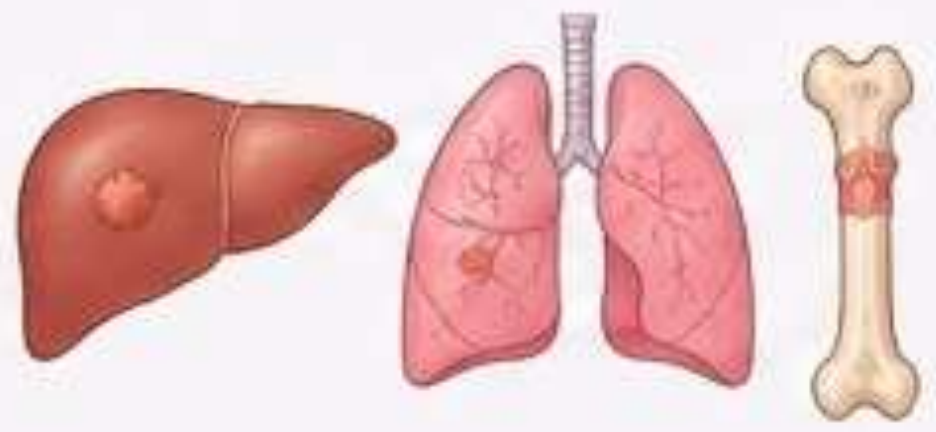

Anatomic Considerations (Esophagus)

Upper thoracic:	Upper thoracic esophagus (inc. thoracic inlet to azygos vein)
Middle thoracic:	Azygos vein to inferior pulmonary vein
Lower thoracic:	Inferior pulmonary vein to diaphragmatic hiatus
Abdominal:	Below diaphragmatic hiatus

Stage Grouping (Esophageal Cancer)

Stage 0	Stage I	Stage II	Stage III	Stage IVA	Stage IVB
Tis N0 M0	T1 N0 M0	T1 N1 M0	T3 N1 M0	T4a N3 M0	Any T Any N M1
	T2 N0 M0	T2 N1 M0	T2 N2 M0	T4b Any N M0	
		T3 N0 M0	T3 N2 M0		
			T4a N0–2 M0		

Note: Staging may vary slightly between histologic types (e.g., squamous cell carcinoma vs. adenocarcinoma) in specific guidelines. Always refer to the latest AJCC/UICC staging manual.

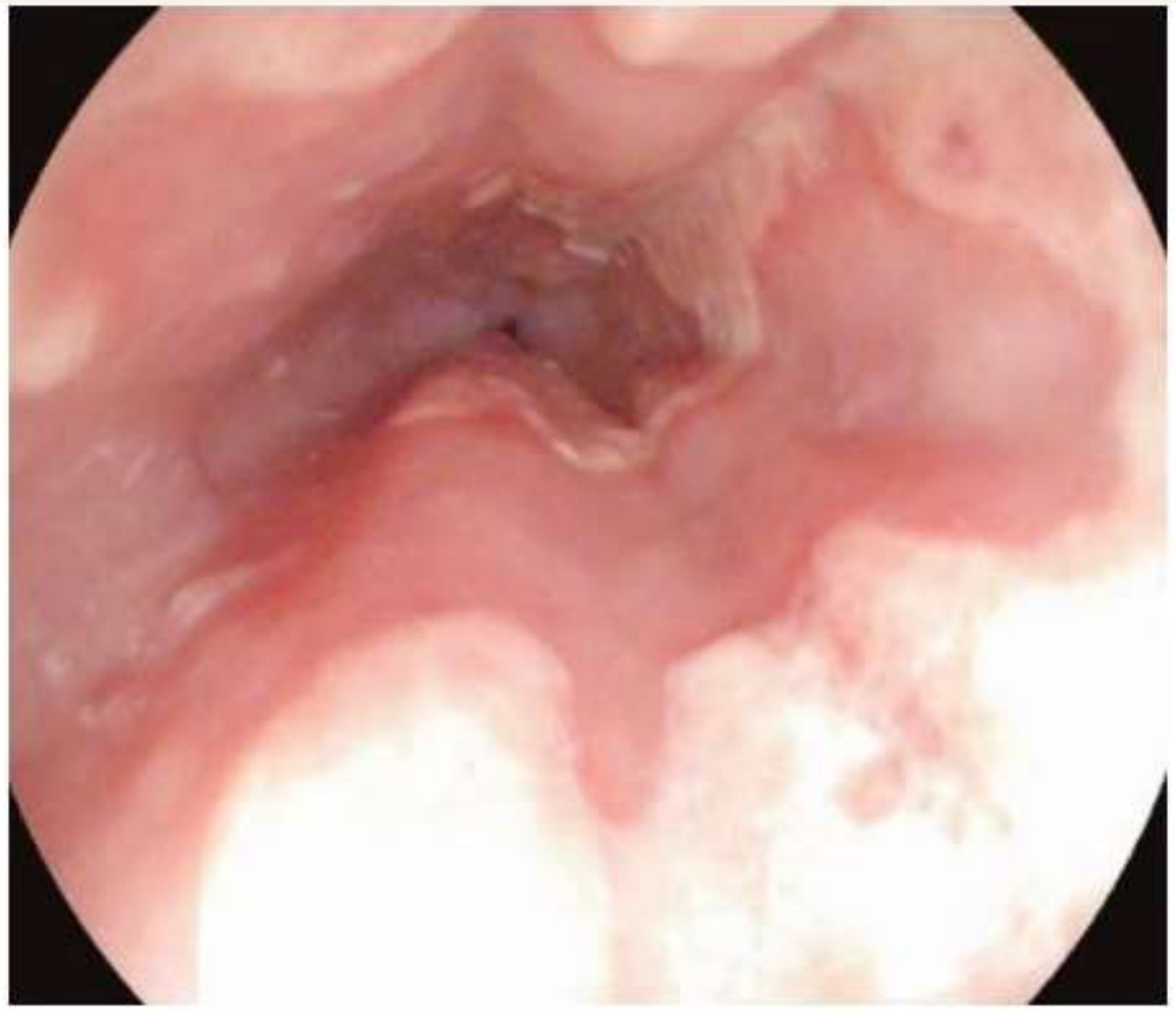

.(Drug-Induced Esophagitis)

Drug-induced esophagitis

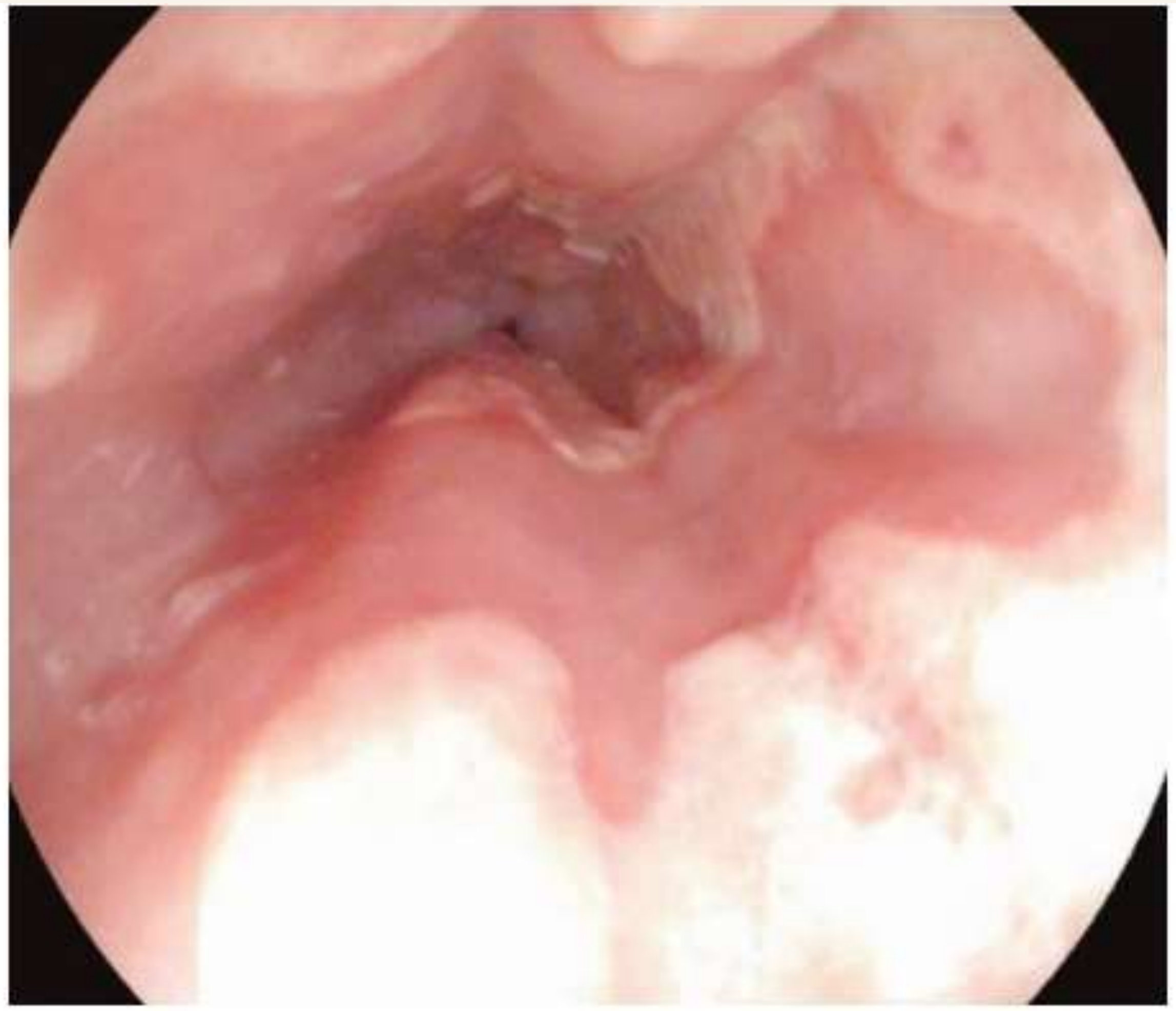

.(Drug-Induced Esophagitis)

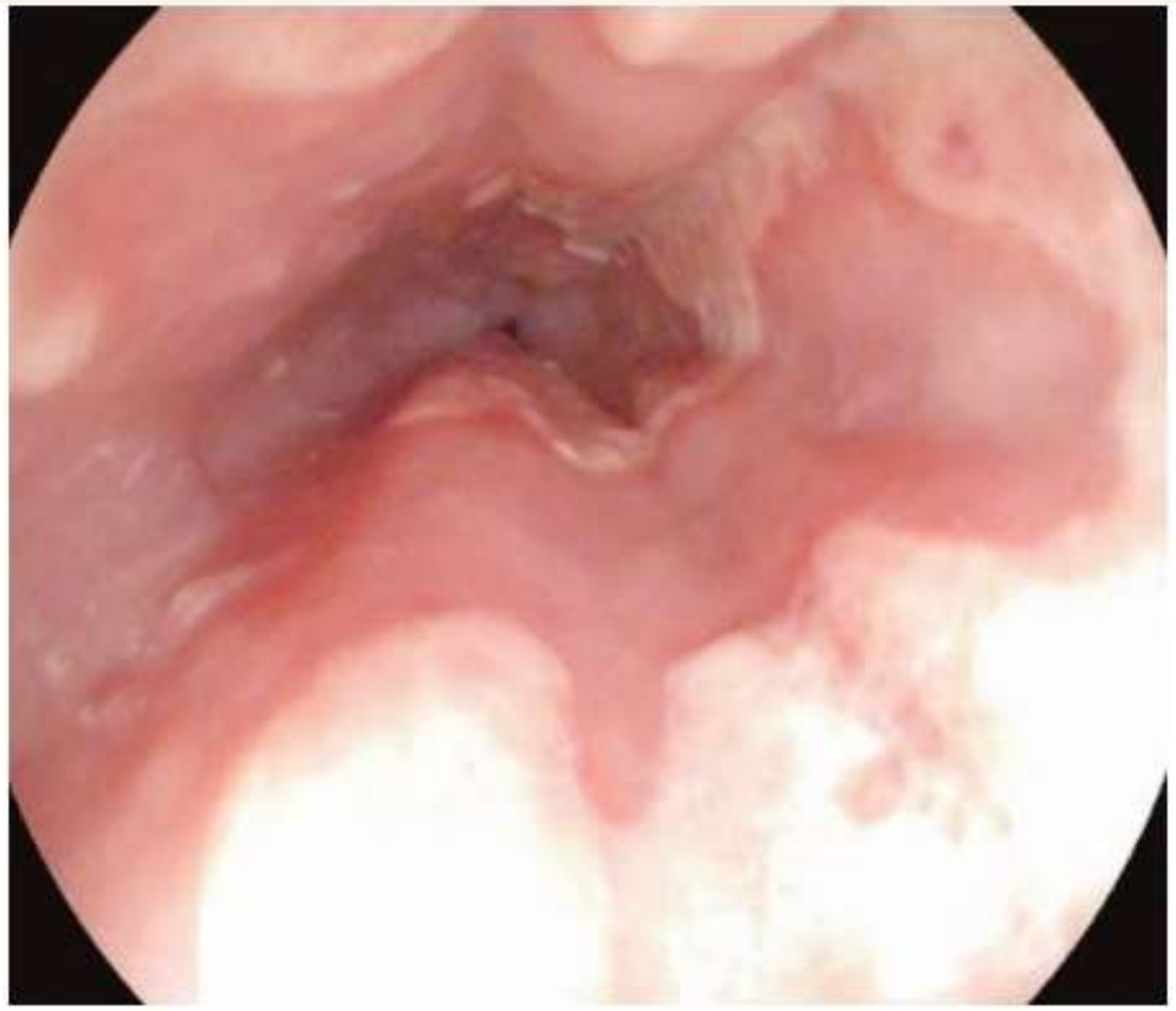

.(Drug-Induced Esophagitis)

Drug-induced esophagitis

- Doxycycline
- Tetracycline
- Clindamycin
- Amoxicillin
- Metronidazole
- Ciprofloxacin
- Bisphosphonates)
- Aspirin
- Ibuprofen
- Methotrexate
- Warfarin
- Ferrous sulfate
- Potassium

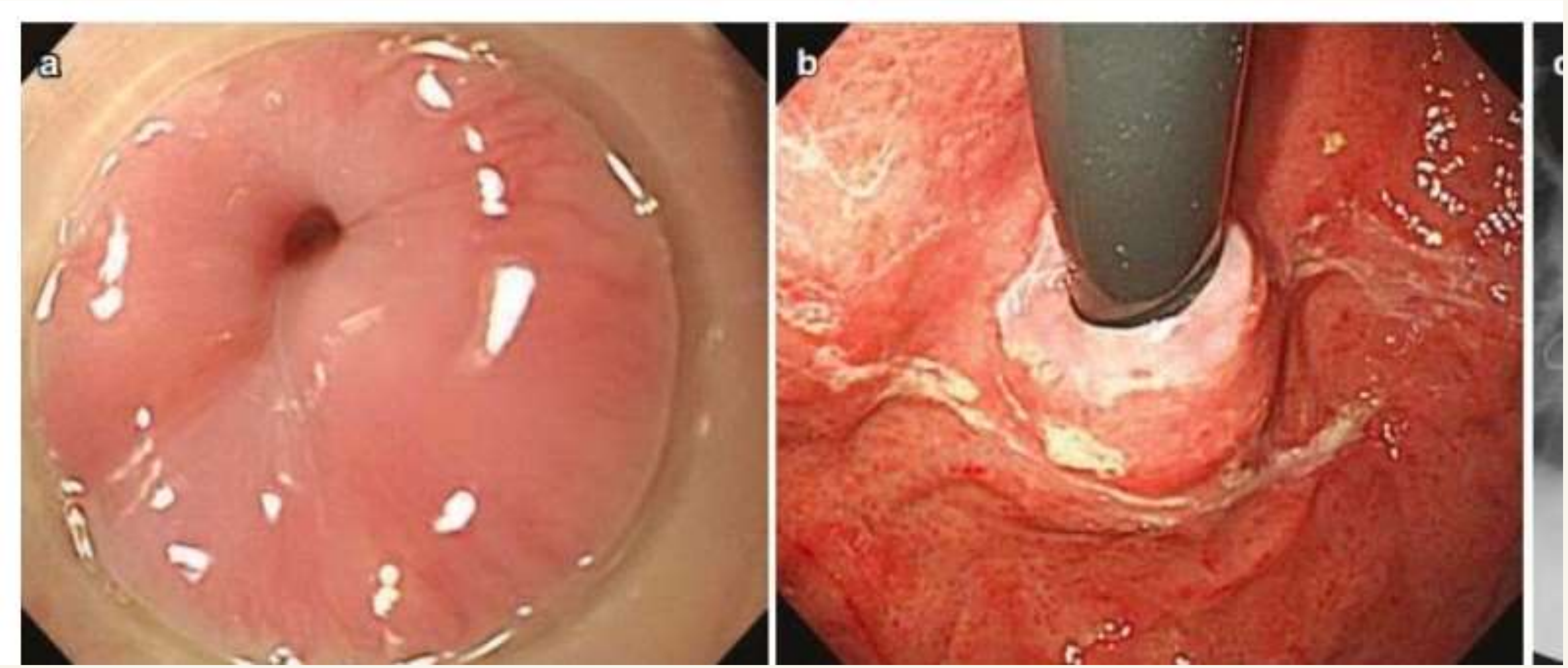
a
b

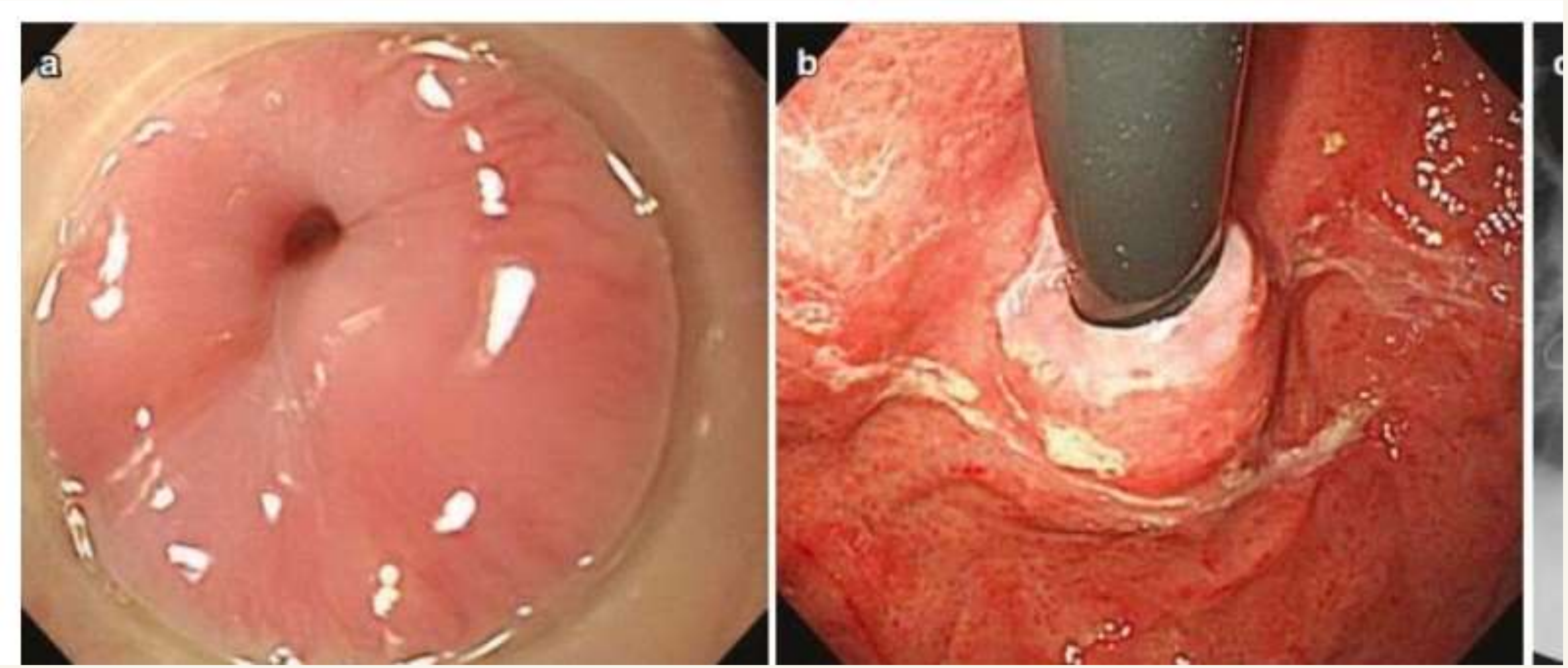

Achalasia

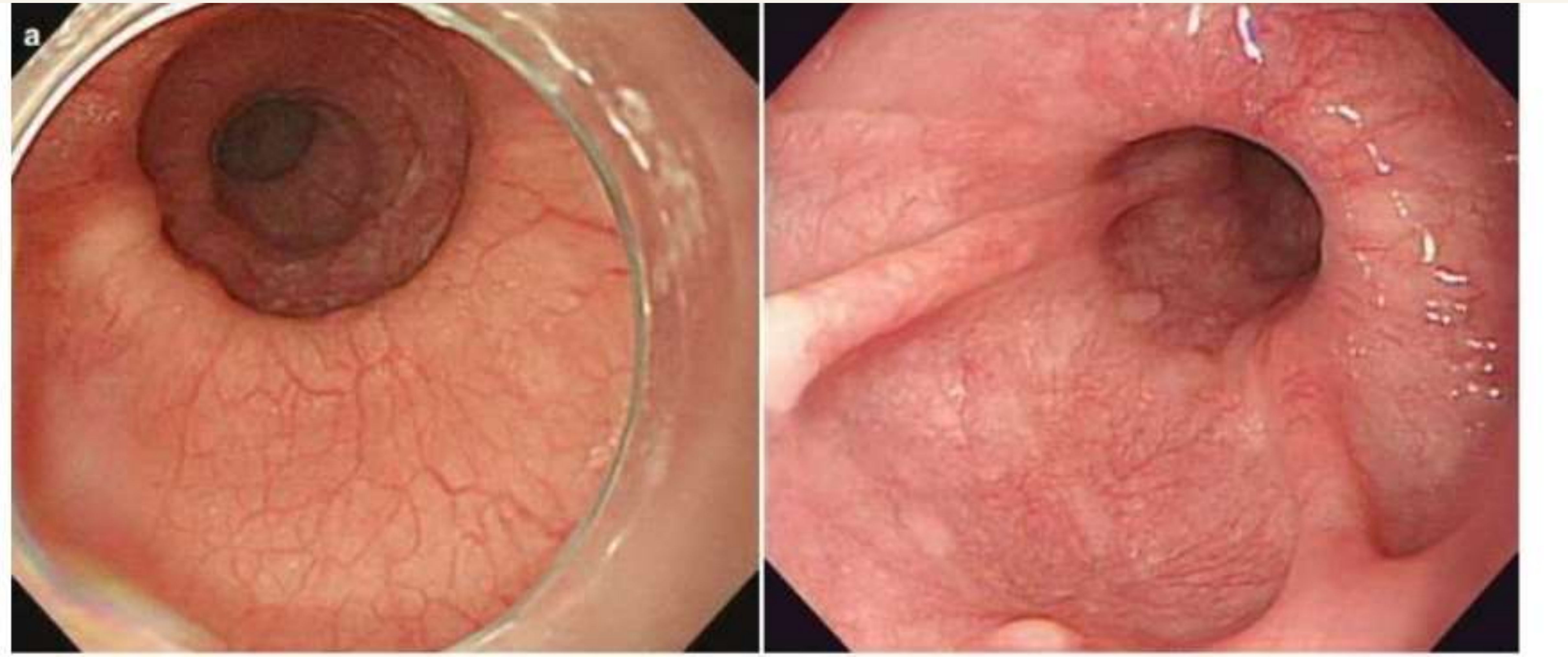
a

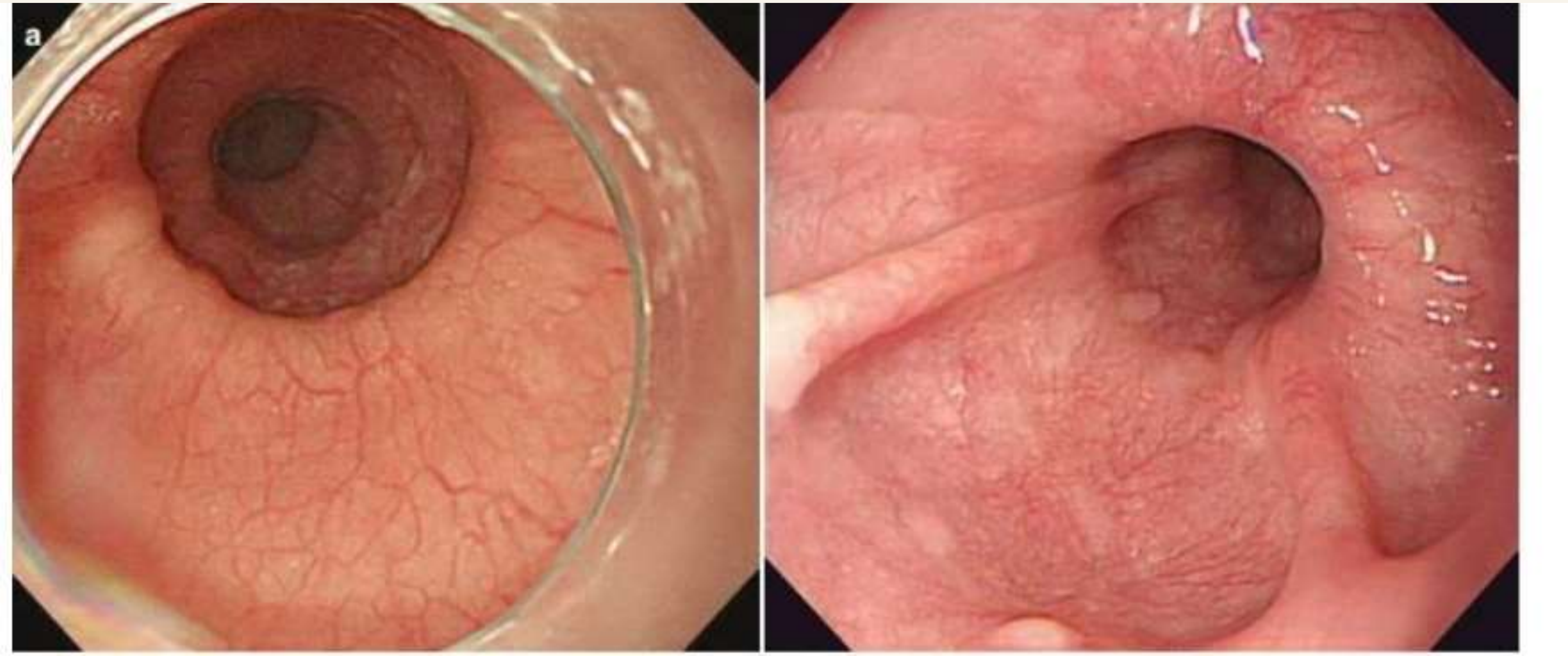

Diffuse Esophageal Spasm

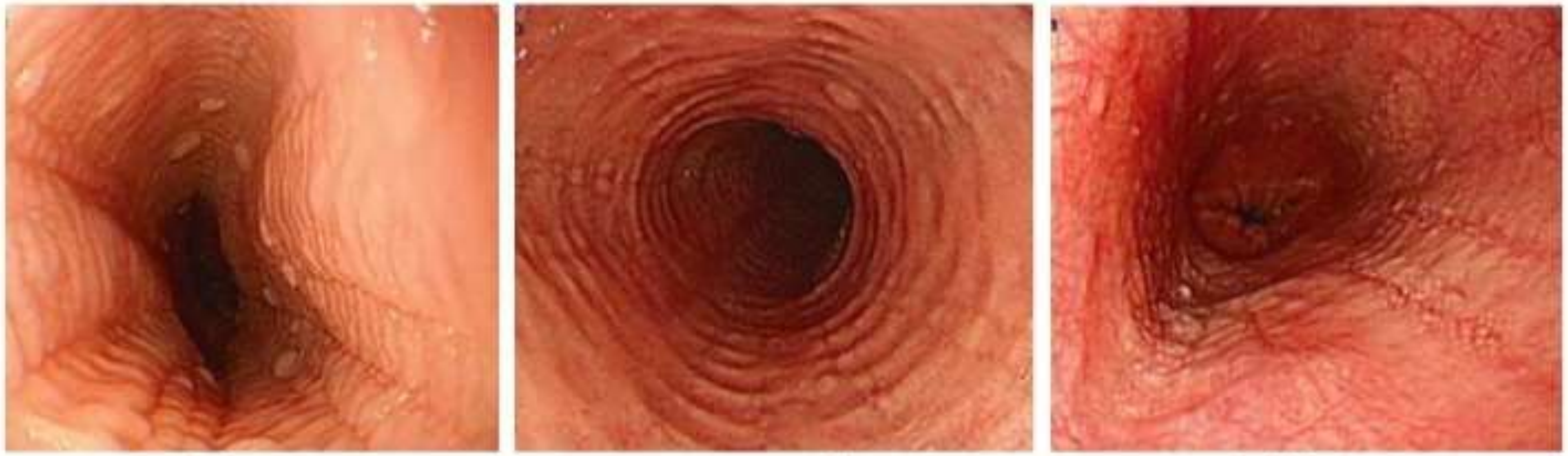

شقوق طولانية

حلقات متعددة

شقوق وحلقات

التهاب المريء بالحمضات

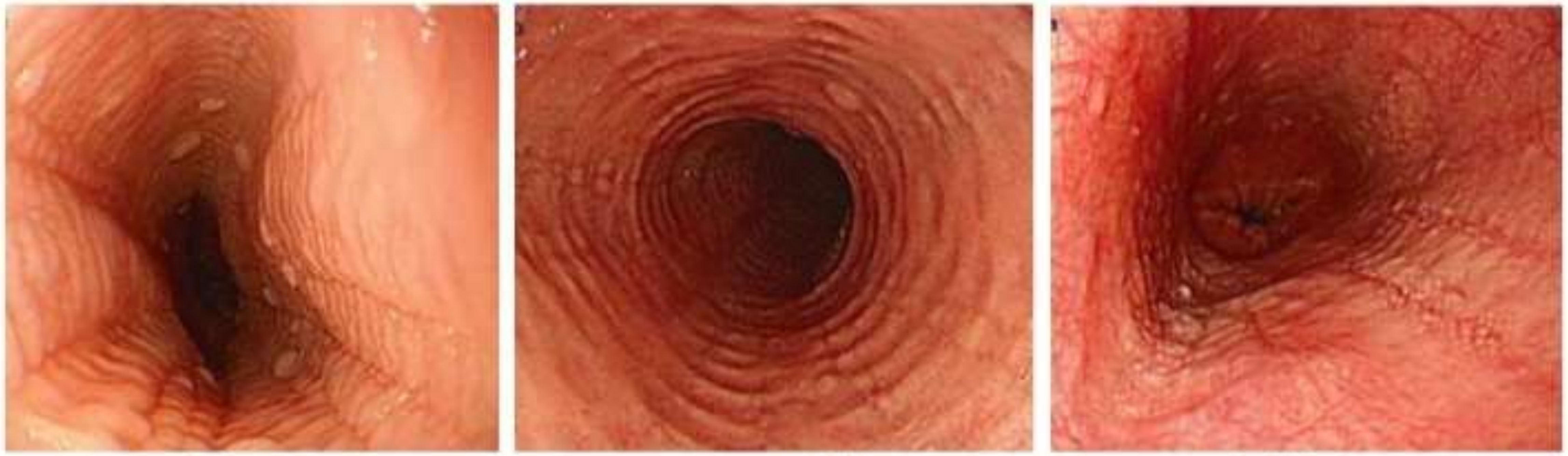

شقوق طولانية

حلقات متعددة

شقوق وحلقات

التهاب المري بالحمضات

Eosinophilic Esophagitis

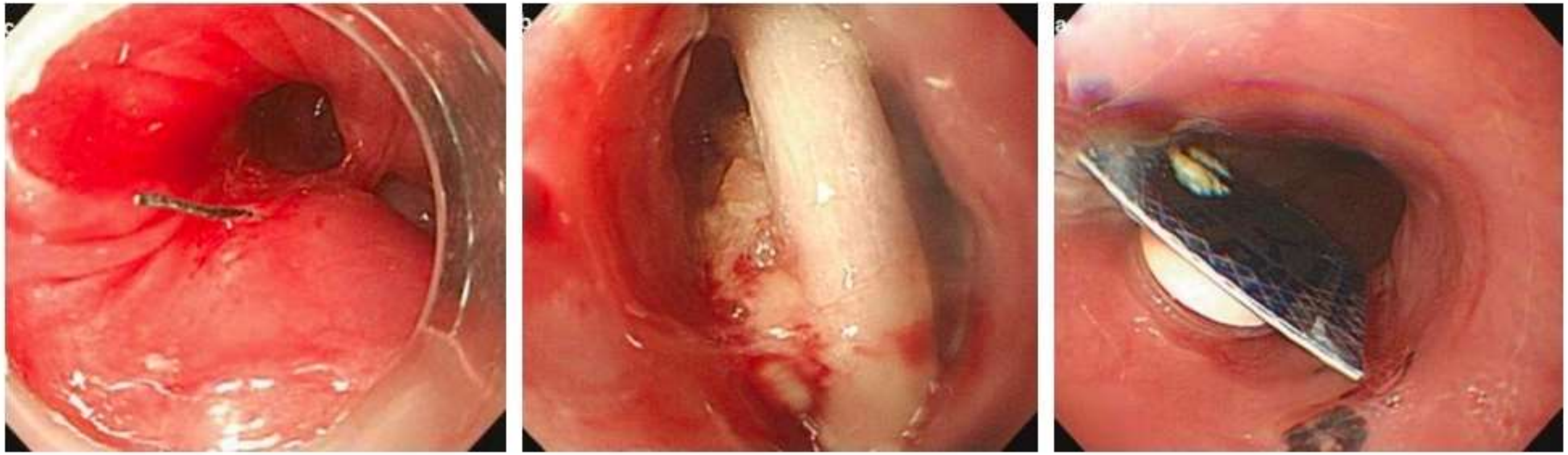

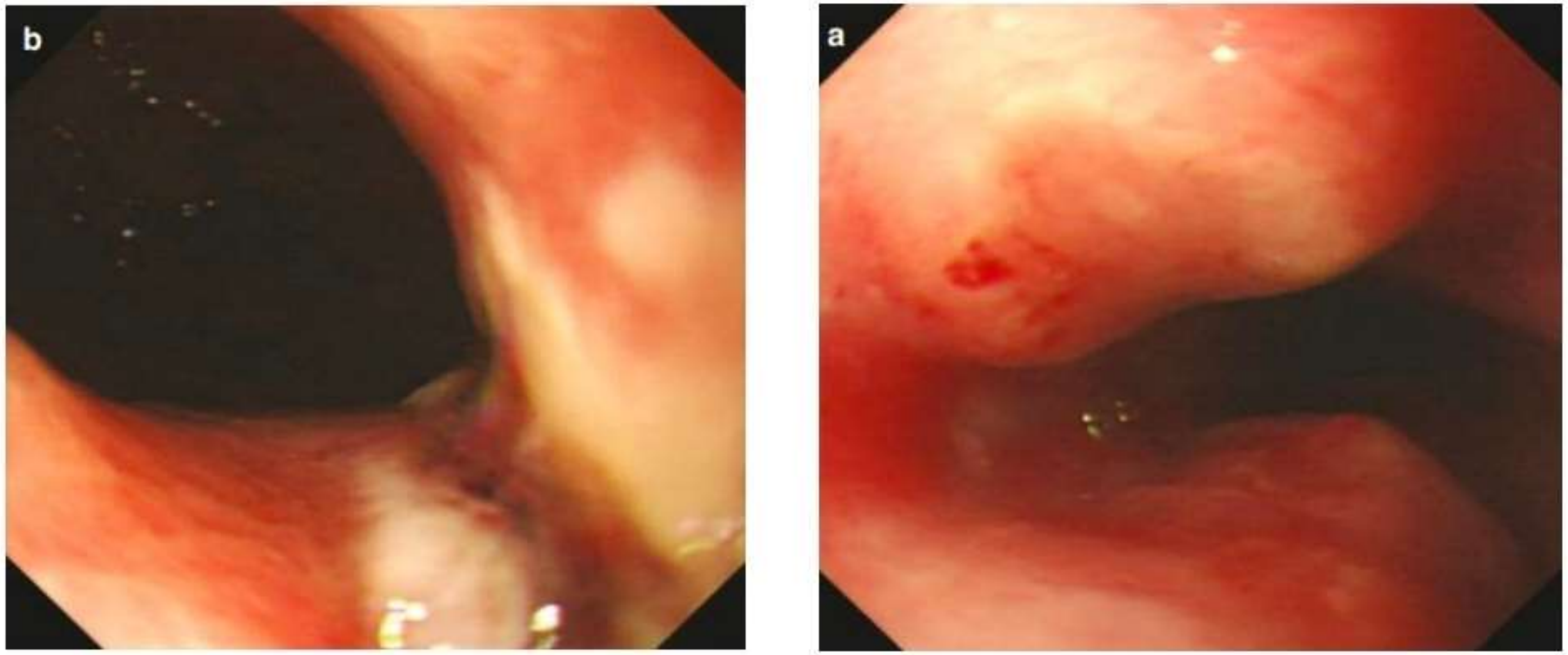

قرحتان طولانيتان متقابلتان في الثلث المتوسط للمري

قرحة طولانية عند الوصل المعدي المريئي لدى نفس المريض السابق

التهاب المري التماسي، بسبب وضع طويل الأمد لأنبوب أنفي معدي

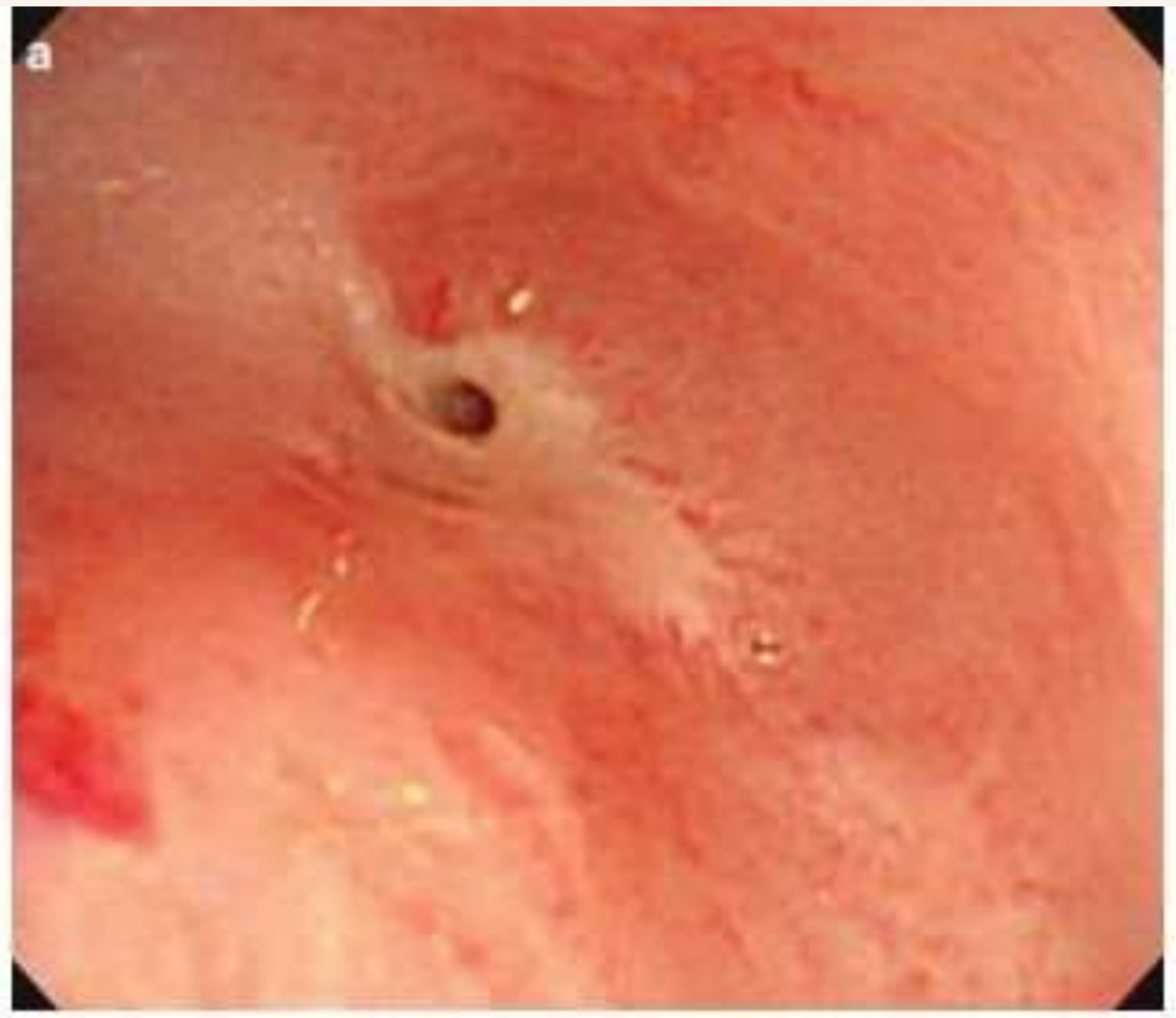

تضيق شديد يعلوه مري باريت طويل القطعة

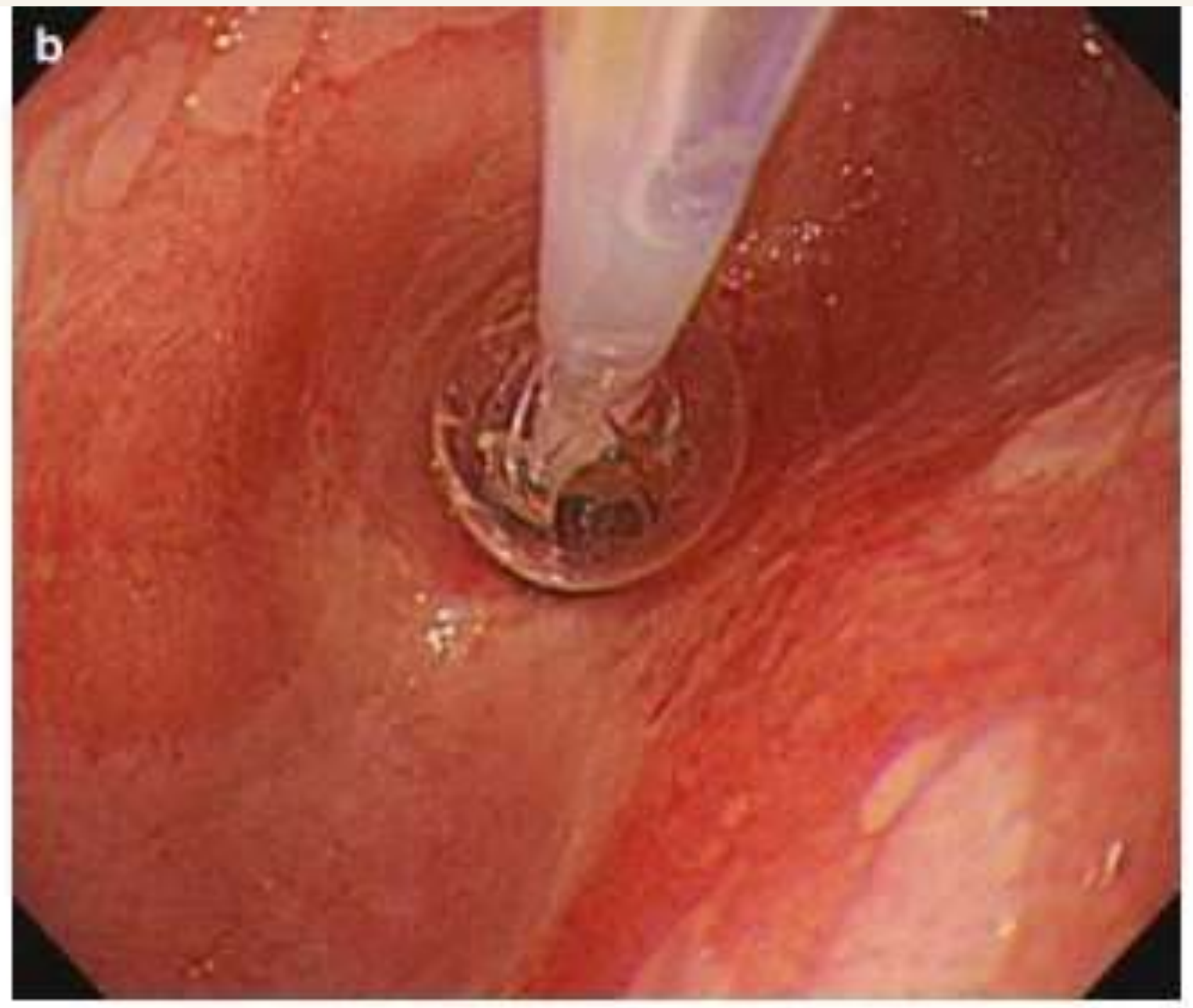

توسيع بالبالون للتضيق السابق

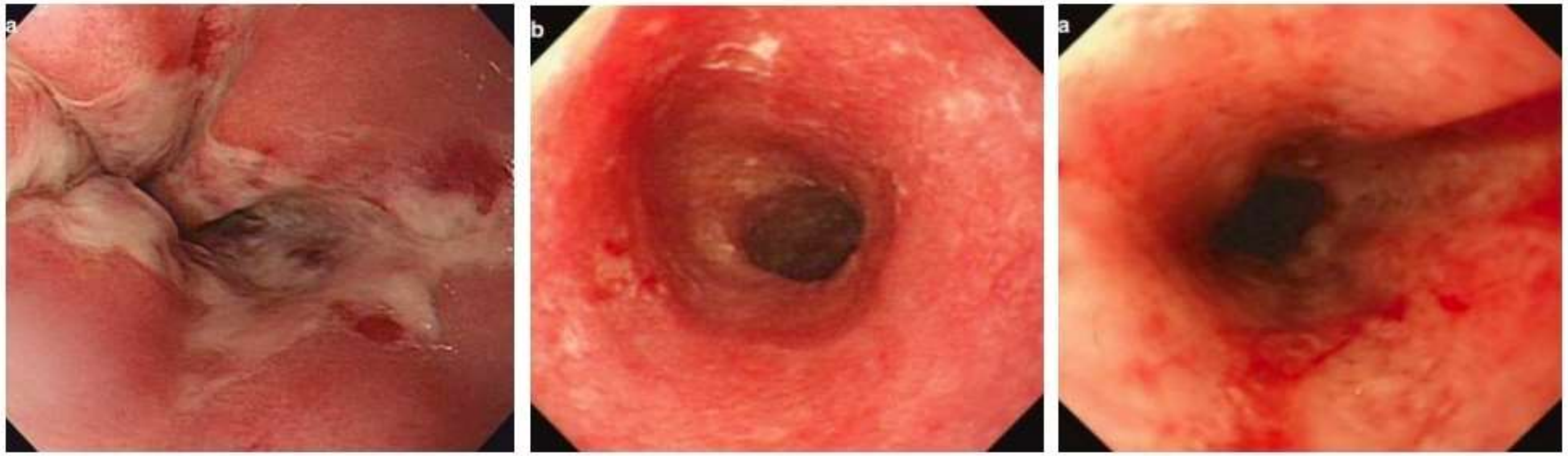

قرحات سطحية في أعلى المري، محاطة بوذمة ونزف

وذمة ونتحة قيحية على امتداد واسع من المخاطية

تقرح على محيط اللمعة، تعلوه اصطباغات تدل على نزف حديث

التهاب المري الإشعاعي

barium esophagram

A barium swallow is used in cases of suspected
Zenker's diverticulum,
when there is concern about perforation after surgery, radiation, or cauterization,
patients with high anesthetic risk.

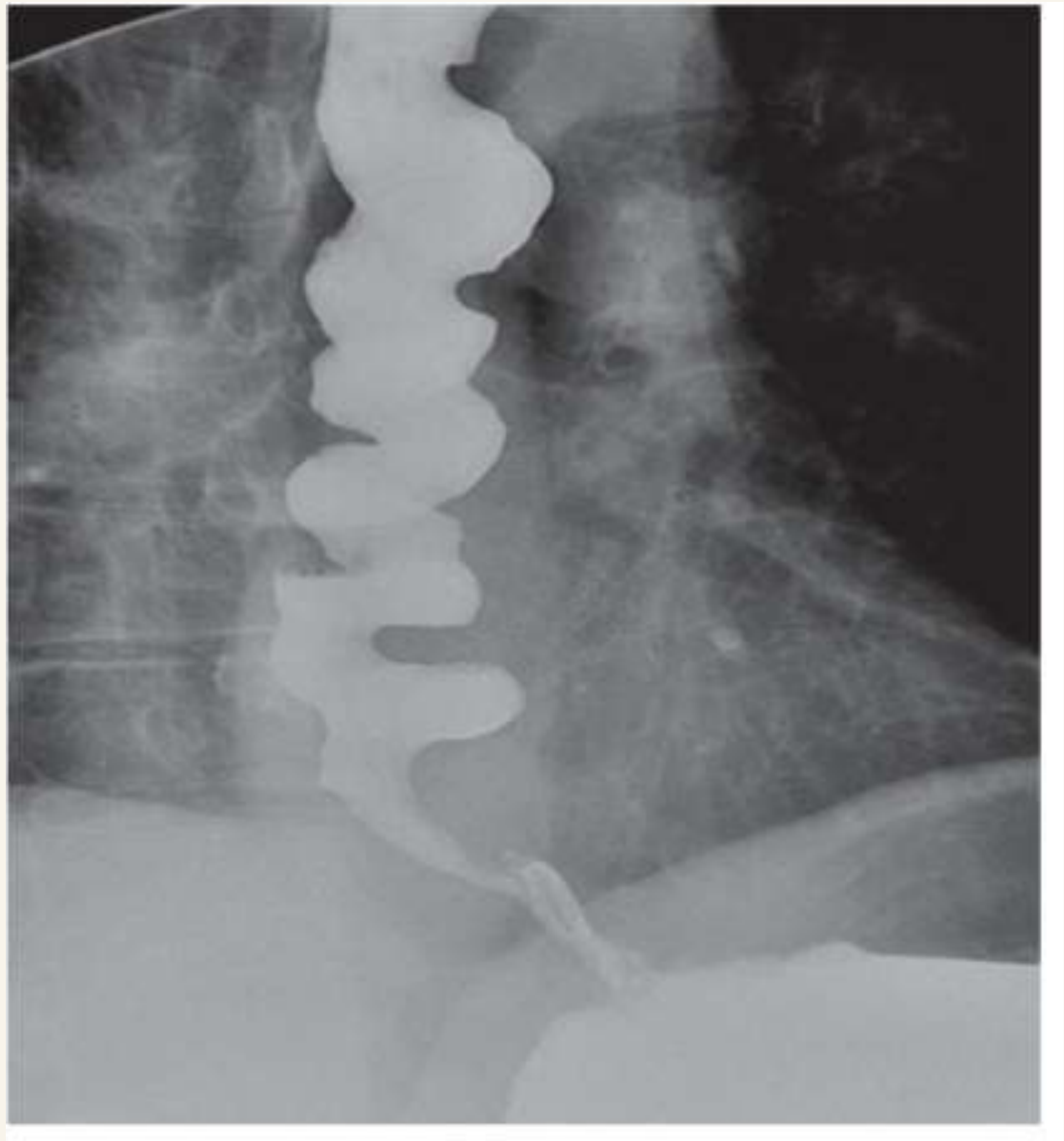

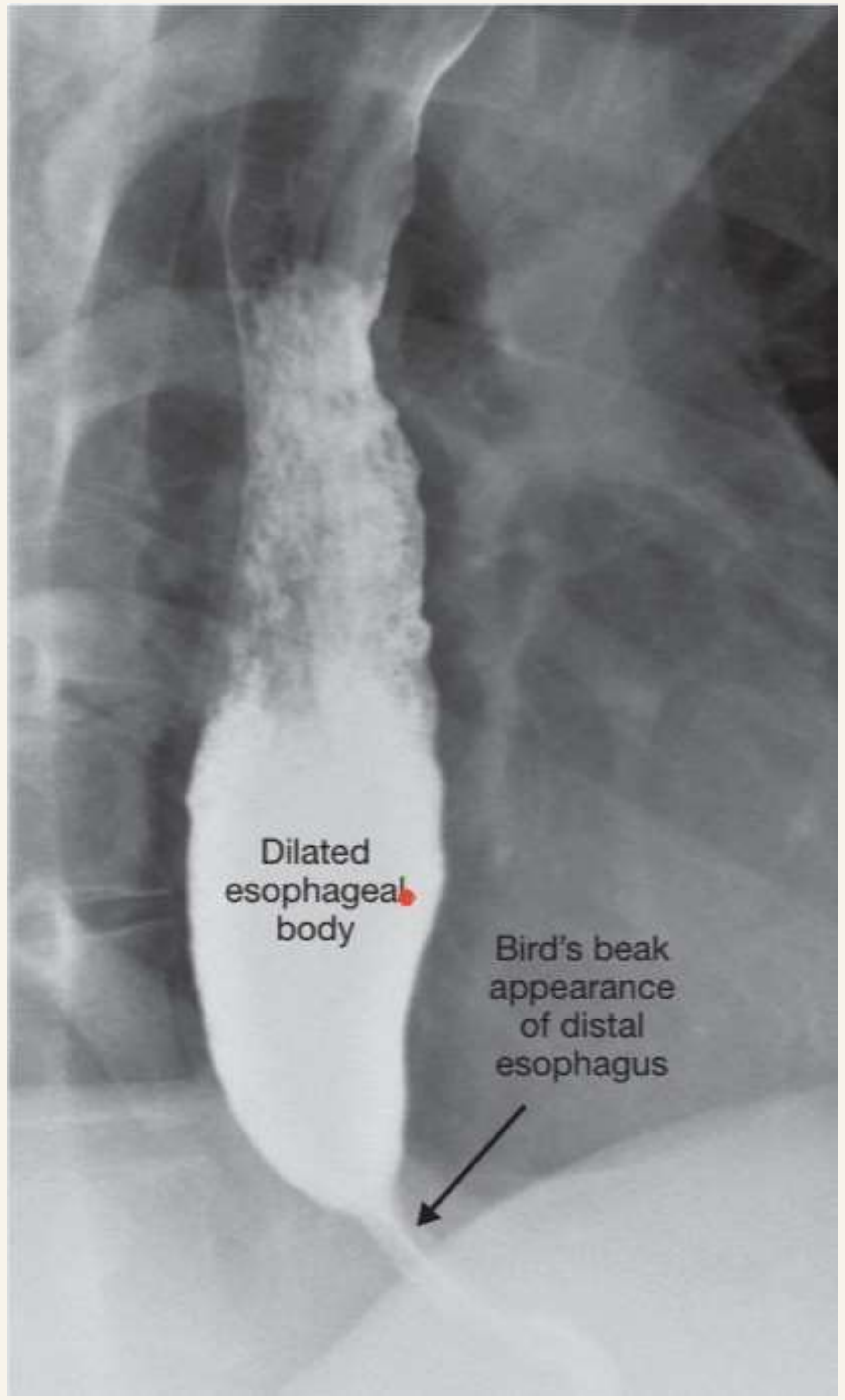
Dilated esophageal body
Bird's beak appearance of distal esophagus

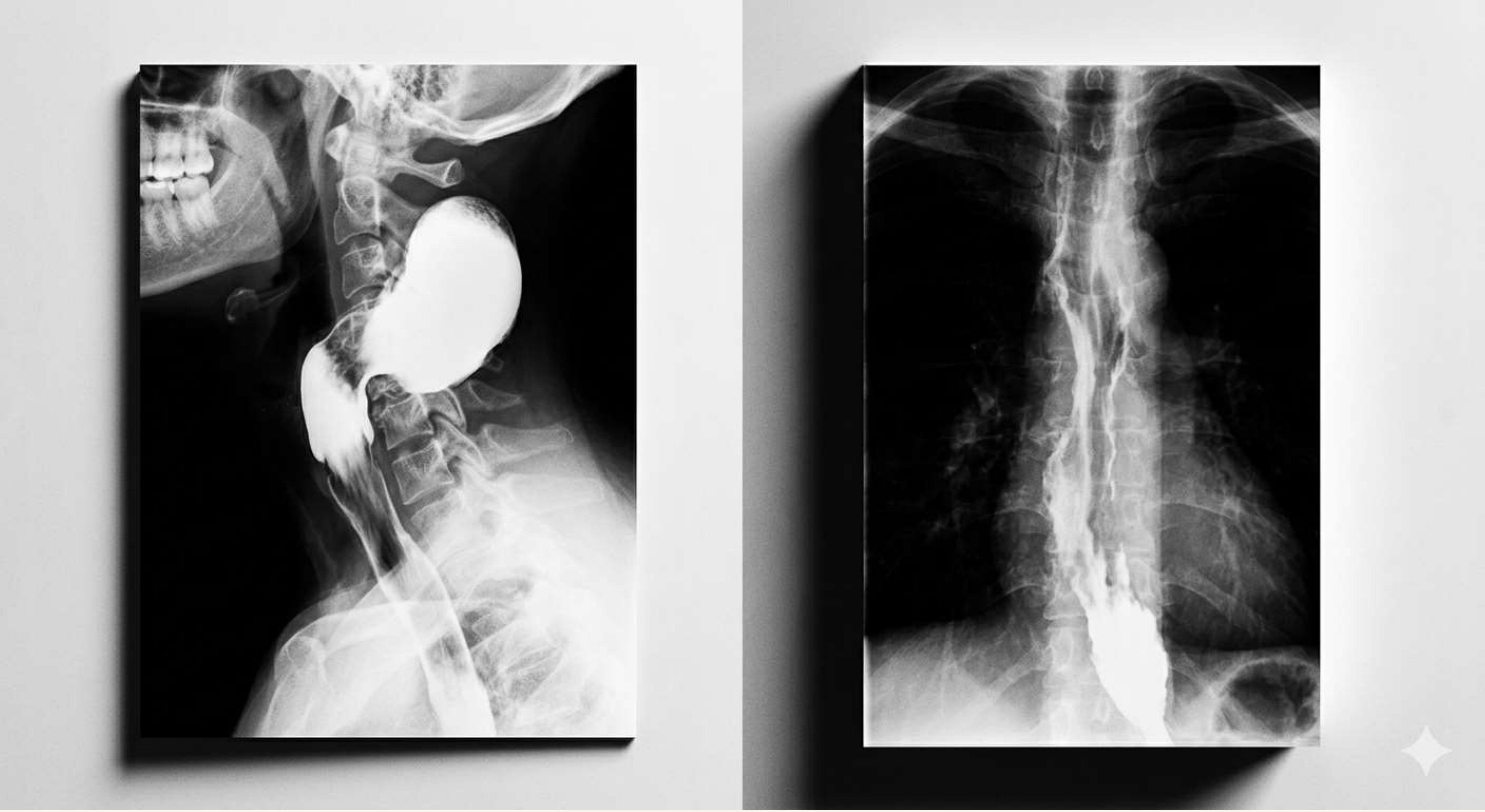

esophageal manometry

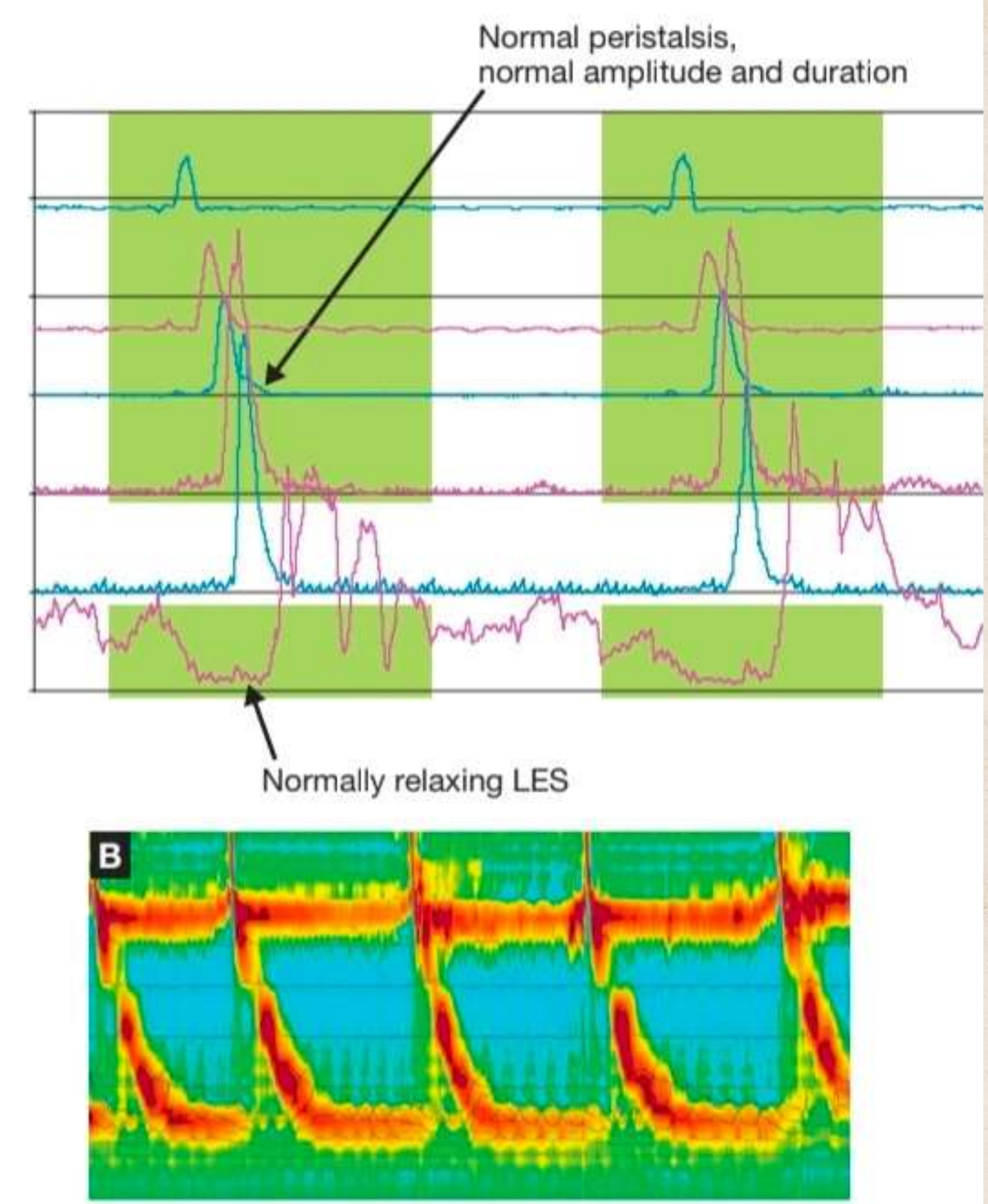
Normal peristalsis,
normal amplitude and duration
Normally relaxing LES
B

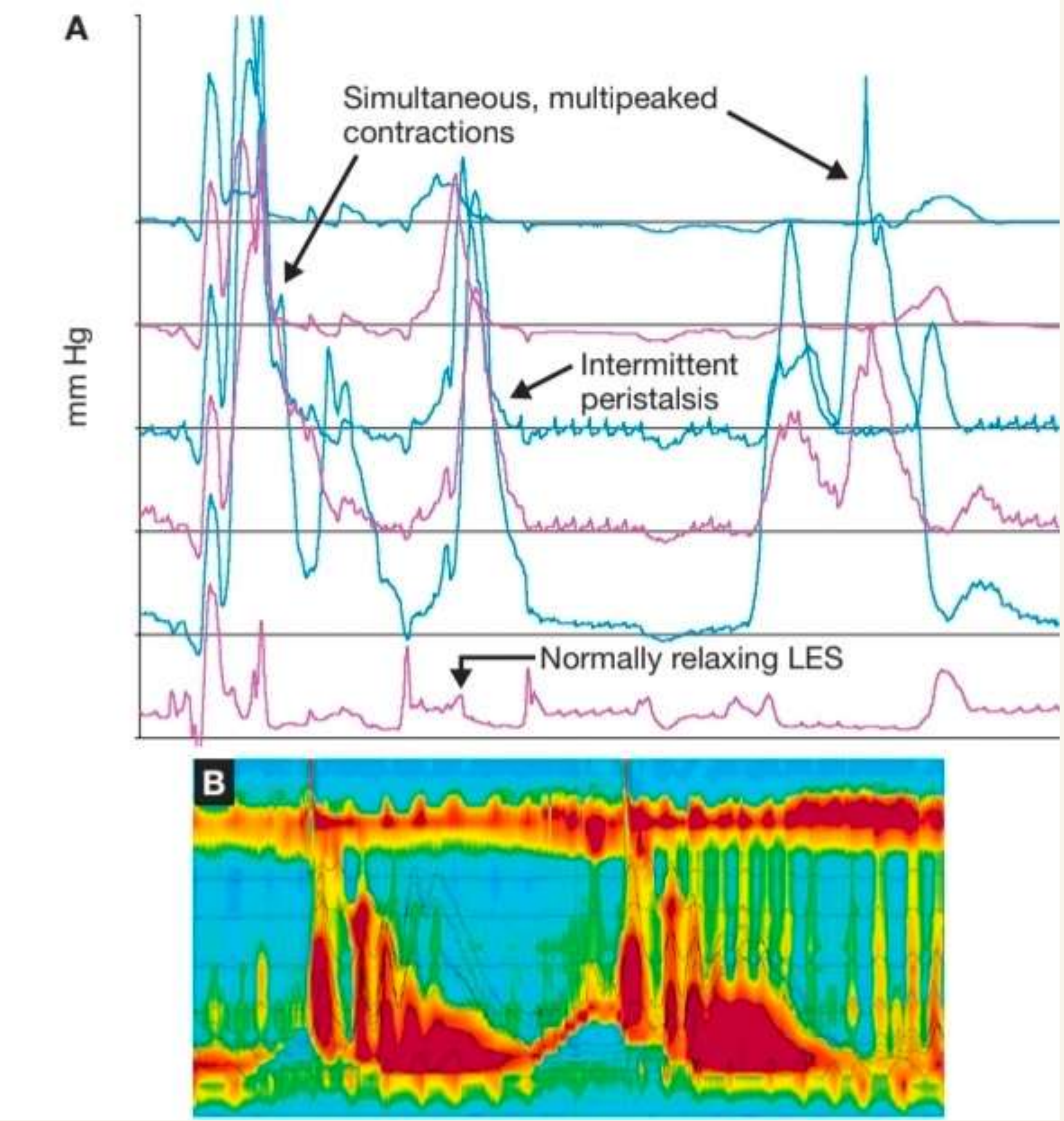
A
mm Hg
Simultaneous, multipeaked contractions
Intermittent peristalsis
Normally relaxing LES
B

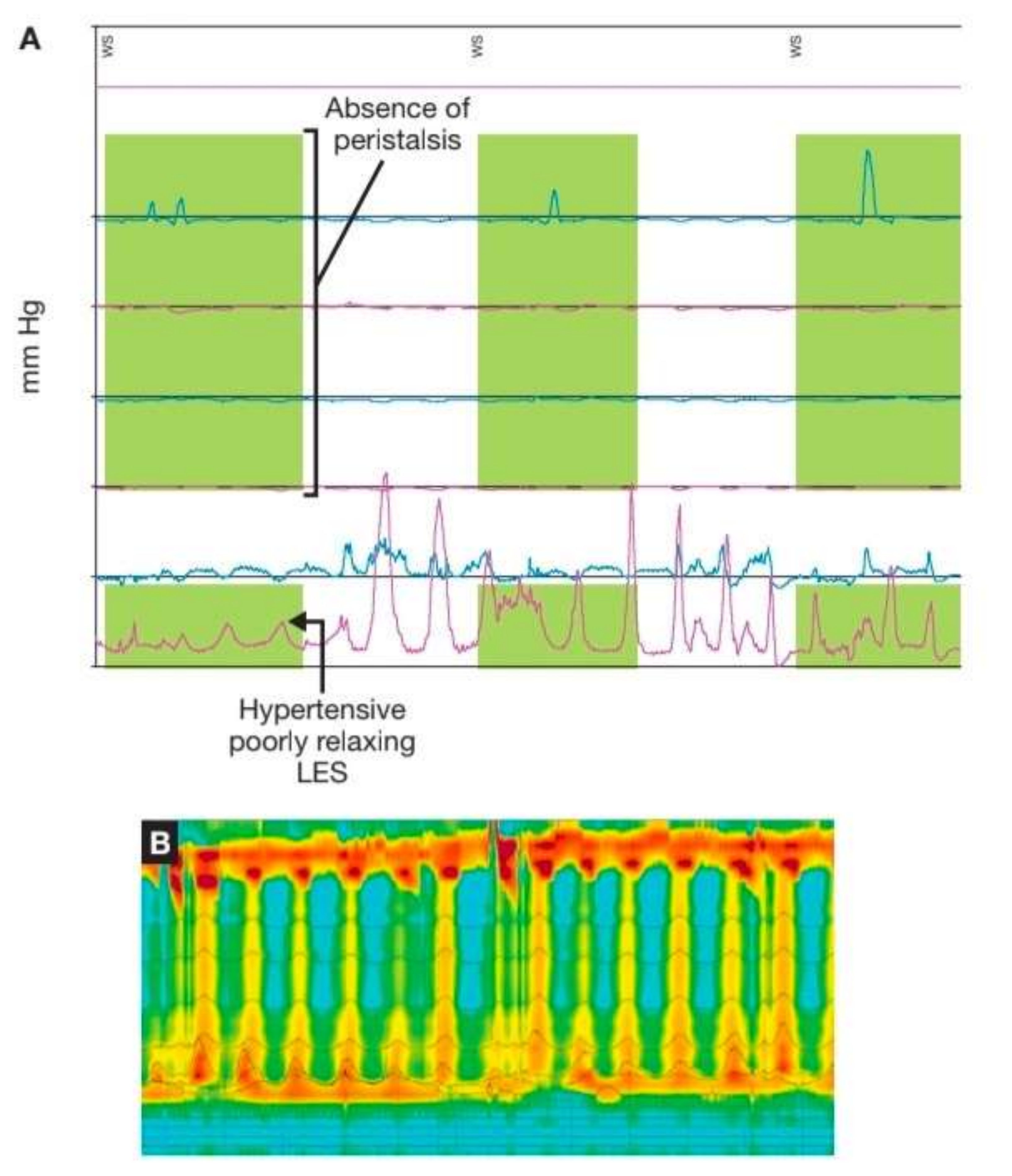
A
WS
WS
WS
mm Hg
Absence of peristalsis
Hypertensive poorly relaxing LES
B

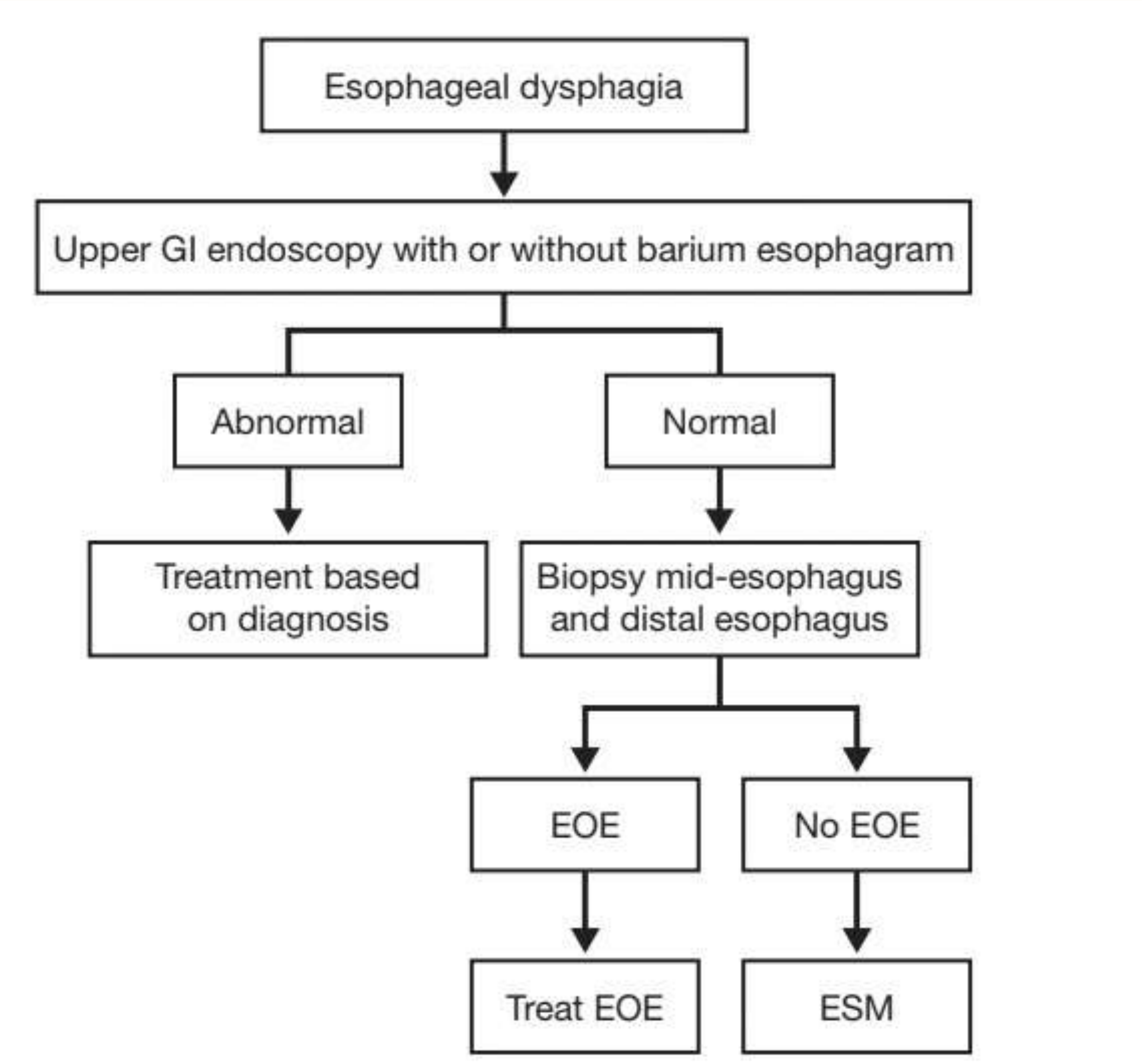
Esophageal dysphagia
Upper GI endoscopy with or without barium esophagram
Abnormal
Normal
Treatment based on diagnosis
Biopsy mid-esophagus and distal esophagus
EOE
No EOE
Treat EOE
ESM

Functional Dysphagia

- Functional dysphagia is defined as dysphagia that persists for at least 3 months, with symptom onset at least 6 months before diagnosis
- normal investigations.
- Management is supportive and includes reassurance and Tricyclic antidepressant therapy.

Q&A Session

A 68-year-old man presents with progressive dysphagia that started with solid foods and later progressed to liquids. He also reports significant weight loss and chronic smoking history. Endoscopy reveals an irregular mass in the lower third of the esophagus.

What is the most likely diagnosis?

- A. Achalasia
- B. Esophageal carcinoma
- C. Gastroesophageal reflux disease (GERD)
- D. Eosinophilic esophagitis

24-year-old man presents with progressive difficulty swallowing solid foods and occasional food impaction. He has a history of asthma and seasonal allergies. Upper endoscopy shows multiple concentric rings and linear furrows in the esophagus. Biopsy reveals high numbers of eosinophils in the esophageal mucosa.

What is the most likely diagnosis?

- A. Achalasia
- B. Gastroesophageal reflux disease (GERD)
- C. Eosinophilic esophagitis
- D. Esophageal cancer

Thank You

Dr. Tasneem aldoki ❤